



JOURNAL

American Holistic Veterinary Medical Association
Volume 34, Fall



RESOLUTION OF A LARGE NON-HEALING WOUND IN A DOG WITH FREQUENCY-SPECIFIC LOW LEVEL LASER THERAPY: A CASE REPORT

Jeff Grognet, DVM, BSc(Agr) and Louise Janes, BSc(Agr), DVM, Mid-Isle Veterinary Hospital,
5 – 161 Fern Road West, Qualicum Beach, British Columbia, Canada, V9K 2K1, 250-752-8969,
HYPERLINK "mailto:jgrognet@shaw.ca" jgrognet@shaw.ca

Conflict of Interest Statement:

Drs. Jeff Grognet and Louise Janes are private practice veterinarians, with no paid connections to the Erchonia Company that manufactured the laser device employed in this case report.

Abbreviations:

FSLLL: Frequency-specific low level laser

Abstract

A 13 yr old male, neutered German Shepherd Dog cross was treated with frequency-specific low level laser therapy (FSLLL) to manage a wound that was unresponsive to 44 days of conventional surgical and medical therapy. Twenty-six FSLLL treatments over a 79 day period were sufficient to clear the infection and close a wound 18 cm by 15 cm.

Introduction

Laser (light amplification by stimulated emission rays) has many diverse applications in veterinary medicine. Its benefit in wound healing has been the focus of attention (1). There are many units available, differing in wavelength, power, and frequency. This paper describes the utilization of an Erchonia low power laser for wound repair.

The Erchonia base station consists of three class 2 heads which are inserted into a charging unit for programming (**Figure 1**). Each head has two diodes that emanate parallel beams. Each diode in the “635a” emits 5 milliwatts (mW) at 635 nanometers (nm) wavelength. The “635b” head has two diodes at 7.5 mW and 635 nm. The “405” head has two diodes with 5 mW beams, one at 635 nm (red beam) and the other at 405 nm (violet beam).

Each diode is programmed with two frequencies that it oscillates between every second (50% duty cycle in each frequency). Each head, therefore, holds four frequencies. If all three heads are utilized at one time, twelve different frequencies are delivered to the patient.

The methodology followed in this case report was developed by Dr. William Inman of VOM Seminars Incorporated. The frequencies originally arose from Rife frequencies developed in the 20th century. Inman utilized these

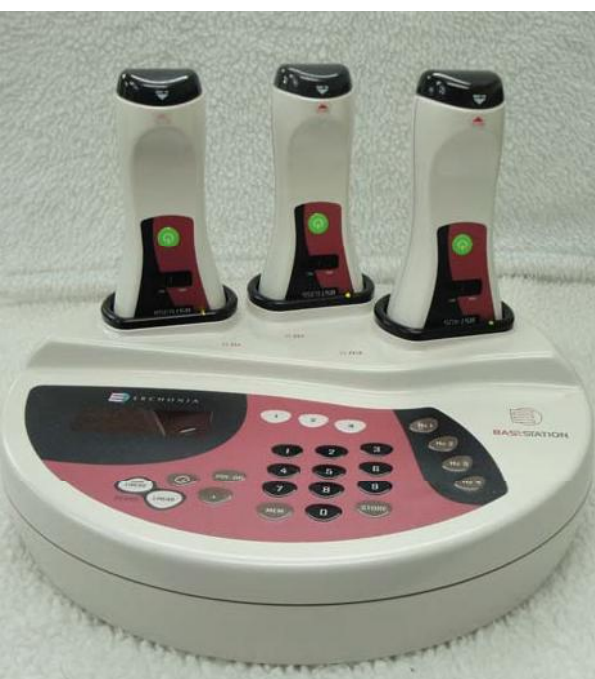

Figure 1 - Erchonia base station.

frequencies in original research and found combinations that worked on specific diseases. A significant number of the human Rife frequencies can be used in animals, but many tend to work better at a higher frequency. It has been postulated that this arises because of animals' higher body temperatures (2).

In this wound management case, the beams were directed to specific locations. The "a" head was directed to the thymic area (cranial chest pointing at the heart). The "b" and "405" heads were directed at the wound itself with the beams sweeping from one edge of the wound to the other in constant, slow motion. Each treatment set was for 180 seconds with the heads positioned 4 to 18 inches from the skin surface.

case study

A 13 yr old male, neutered German Shepherd Dog cross was presented with a large wound over his left hip. The owner reported that there had been a small wound present for several weeks that he was self-treating with amoxicillin and ibuprofen^a at unknown doses.

The patient was an outside dog, able to roam at will. Contact with other dogs and wildlife was possible. His diet was a low-quality, dry commercial food with occasionally offerings of scraps from the table. The dog's weight on initial assessment was 38 kg.

On presentation, the area of skin loss was approximately 20 cm in diameter, with a cavity outlined below the skin edges. The origin of the wound was never determined, but a large abscess was considered.

The clinical chronology of this case is reported with day 0 being the first day of laser therapy. Days prior to laser therapy are reported as negative days.

Day - 44: The wound was debrided to remove dead tissue adhering to the skin edges. Hydrotherapy was instituted for five minutes, three times a day. The antibiotic marbofloxacin^b was given (2.6 mg per kg q 24 hr). The next day, tramadol^c (200 milligrams q 8 hr prn), was dispensed to address discomfort.

Day - 38: The epidermal layer sloughed in specific areas, presumably due to damage from the initial insult. Three large

In Inman's methodology of using the Erchonia base station, the "a" head targets either the thymic area (tissues of the heart) or the brainstem (corpus callosum). The rationale for putting the "a" head at these locations is that much of the body's energy is generated by these major energy centers; by directing the laser to these sites, the success rate of therapy is significantly increased (2).

The base station has been used in our practice for an array of diseases, including, but not restricted to, arthritis, disc prolapse, liver disease, incontinence, cruciate ligament rupture, fibrocartilagenous emboli, epilepsy, chronic renal disease, infections, inflammatory bowel disease, wound healing, allergies, colitis, and cystitis.

mattress sutures were placed temporarily to bring the wound edges closer together. The anti-inflammatory meloxicam^d was added (0.1 mg/kg q 24 hr). This was not used initially because of possible interactions with the ibuprofen given by the owner.

Day - 29: Surgery was scheduled for this day but was postponed because the skin did not look viable. Blood and urine tests were submitted for analysis. Tension sutures were put in utilizing local anesthetic to close the wound as much as possible and drains were installed. The antibiotic was changed to metronidazole^e (20 mg/kg q 24 hr).

Day - 26: The patient was feeling better and eating well. This was attributed to the change in antibiotics and the partial wound closure.

Blood tests (True North Veterinary Diagnostics) indicated a mild, non-regenerative anemia with the hematocrit 34.4 (reference range 42.0-62.0) and reticulocyte count of 1%. The white blood cell count was elevated at 21.1 x10⁹ per liter (reference range 4.5-13.0) with an abundance (78%) of neutrophils and elevated eosinophils (8%). The pathologist suggested that these latter changes, along with an elevated globulins of 43 g/liter (reference range 20-40), were consistent with chronic inflammation.

Day - 24: Trimethoprim-sulfamethoxazole^f at 19 mg/kg q 12 hr was added.

Day - 19: The dog escaped confinement and reopened the wound. Because the skin defect could not be closed directly, an advancement technique was recommended.

Day - 15: Surgery performed. Under general anesthetic, infected tissue was debrided. The skin was sutured without tension over a 2 inch distance on the dorsal aspect of the wound and another 2 inches on the ventral aspect of the wound. The central part of the wound could not be closed due to excessive tension. As an advancement technique, four loops of 2-0 Braunamid[®] were put in the cranial and caudal aspect of the defect and umbilical tape was used to shoelace the two sides closer. The open skin area still measured about 10 cm by 10 cm.

The defect was covered with pasteurized (edible) honey and a non-adherent pad (held in place with the lacing) to promote healing and eradicate bacteria. Two Penrose drains were installed. Meloxicam as well as both antibiotics were continued post-operatively.

Day - 1: The entire left hind leg from upper thigh through to the digits was swollen with pitting edema and a portion of the skin edge was necrotic. The tissue surrounding the wound was hot to the touch. The patient was eating little and developed epistaxis with constant dripping of blood-tinged fluid from his nostrils. The bleeding was perhaps an anti-platelet adverse reaction to the potentiated sulfonamide antibiotic. His body temperature was 39.3°C.

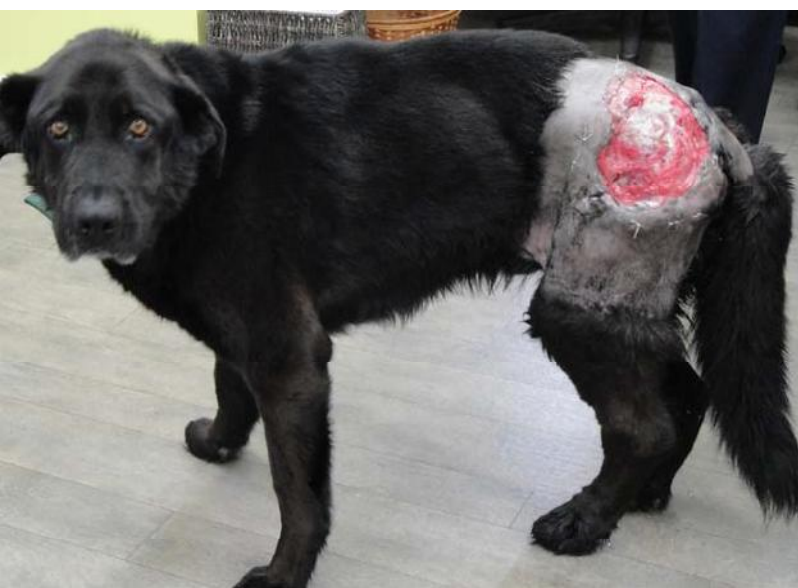

Figure 2 - Day 0 (first day) of FSLLL therapy.

His weight had dropped to 33.2 kg.

At this point, the owner was considering euthanasia. FSLLL therapy was offered as an alternative to conventional treatment.

Day 0: First day of FSLLL therapy: All medication except the anti-inflammatory Meloxicam was discontinued. The wound was cleaned, the necrotic skin edge was excised, all sutures were removed, and the wound was covered with a T-shirt to prevent licking. The wound measured 18 cm by 15 cm. There was a pocket around the entire wound to a depth of 2 to 6 cm depth (**Figure 2**). Note the patient's depression and the severity of the limb edema.

Treatment consisted of hydrotherapy that was accompanied with light debridement using a moist gauze pad, 10 minutes once daily. FSLLL therapy was started using the Erchonia base station. The frequencies used are listed in table 1. Frequency sets A, B and C were used twice daily for three days, then once daily for four days.

A sample of viable tissue at the wound edge was removed and submitted for histopathology^h. The histopathological diagnosis was granulomatous cellulitis. Stains for acid-fast bacteria and fungal elements were negative. No tumor was detected. Though never confirmed, a diagnosis of sterile granulomatous panniculitis was considered as an inciting cause of this wound.

Day - 2: The patient's appetite had increased substantially and the wound and the surrounding tissues were not as hot to the touch. His body temperature had dropped to 38.7°C and the epistaxis had resolved.

Day - 9: Small areas of the skin edge had adhered to the underlying muscle. The edema of the stifle and tarsus had resolved but a small amount persisted in the metatarsal and phalangeal region.

Day - 12: The edema had completely resolved. The frequencies for lymphatic drainage were stopped and additional frequencies for wound healing and inflammatory pockets were added. (See **Table 1** for frequency sets D, E and F.) One-third of the skin edge was adhered and the defect was beginning to contract. The infection was eradicated and the dog was starting to play. The therapy was continued once a day for five days.

TABLE 1: LASER FREQUENCIES USED TO MANAGE A LARGE, NONHEALING, INFECTED WOUND WITH COMPLICATING LIMB EDEMA

	"a" head	"b" head	"405" head
A. Wound healing	4-33-60-151	363-25-100-52	4-45-20-20.5
B. Lymphatic drainage	15-42-250-230	20.5-100-146-363	45.2-1699-279-111
C. Infection	784-73-20-5000	10000-250-36-42	224.46-111.74-100-97
D. Wound healing	4-33-60-151	363-25-100-52	4-45-20-20.5
E. Inflammatory pockets and wounds	4-33-60-151	153-784-279-111	20.5-363-230-42
F. Infection	784-73-20-5000	10000-250-36-42	224.46-111.74-100-97
G. Wound healing	4-33-60-151	363-25-100-52	4-45-20-20.5
H. Inflammatory pockets and wounds	4-33-60-151	153-784-279-111	20.5-363-230-42
I. General pain and inflammation	9-16-42-53	216-66-96-43	8166-45.2-20.5-1260

Day - 20: The underlying muscle tissue was very clean and erythematous, likely due to improved circulation. Since the infection appeared to be resolved, the infection frequencies were discontinued and replaced with frequencies for general pain and inflammation. The new protocol (G, H, and I) was continued twice weekly until day 48.

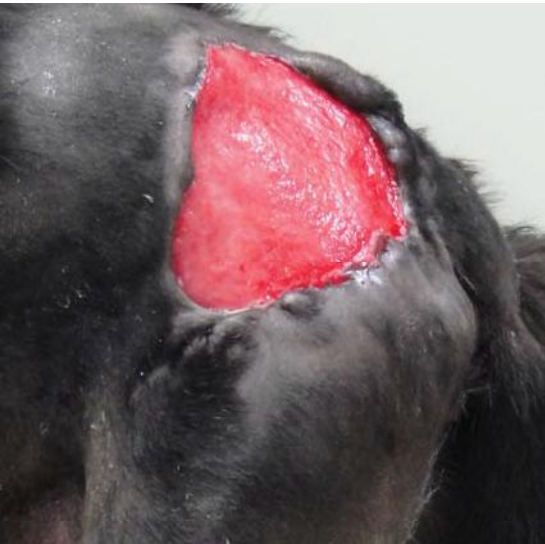

Figure 3 -Day 29 of FSLLL therapy.

Day - 29: The wound looked very healthy and was seeping very little. Over two-thirds of the skin edge had adhered and the wound was contracting daily. The pockets on the non-attached edges were significantly narrower (**Figure 3**).

Day - 36: Almost all the edges were firmly adhered. There was only one persistent pocket still present along the cranioventral aspect of the wound. The defect measured 9.5 cm by 9.0 cm.

Day - 48: Contraction continued. Meloxicam was discontinued because

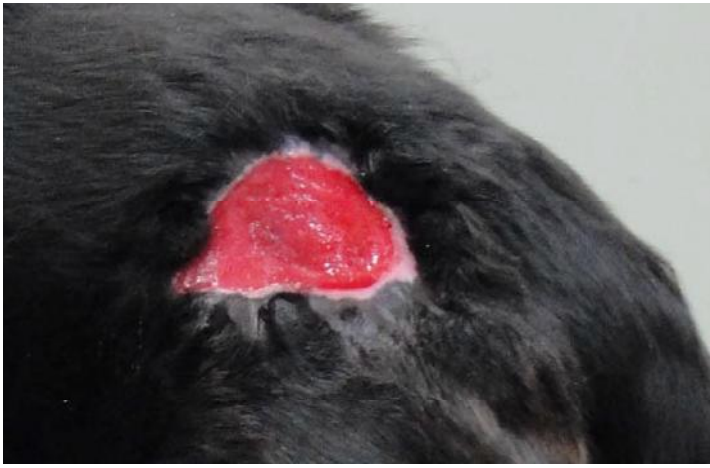

Figure 4 - Day 62 of FSLLL therapy.

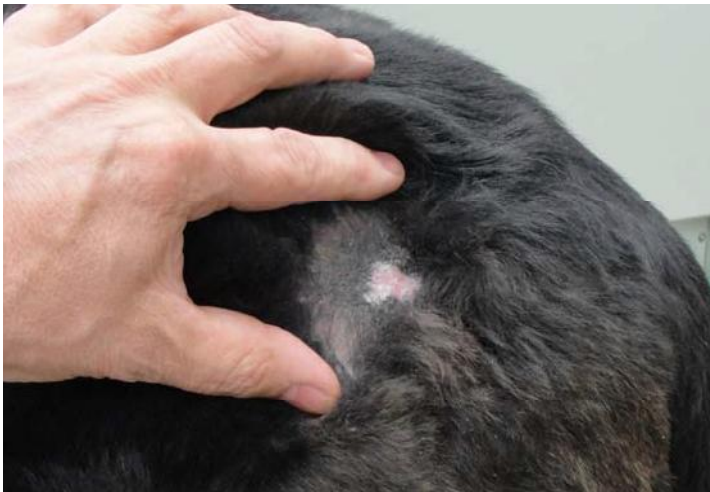

Figure 5 - Day 132 (final assessment).

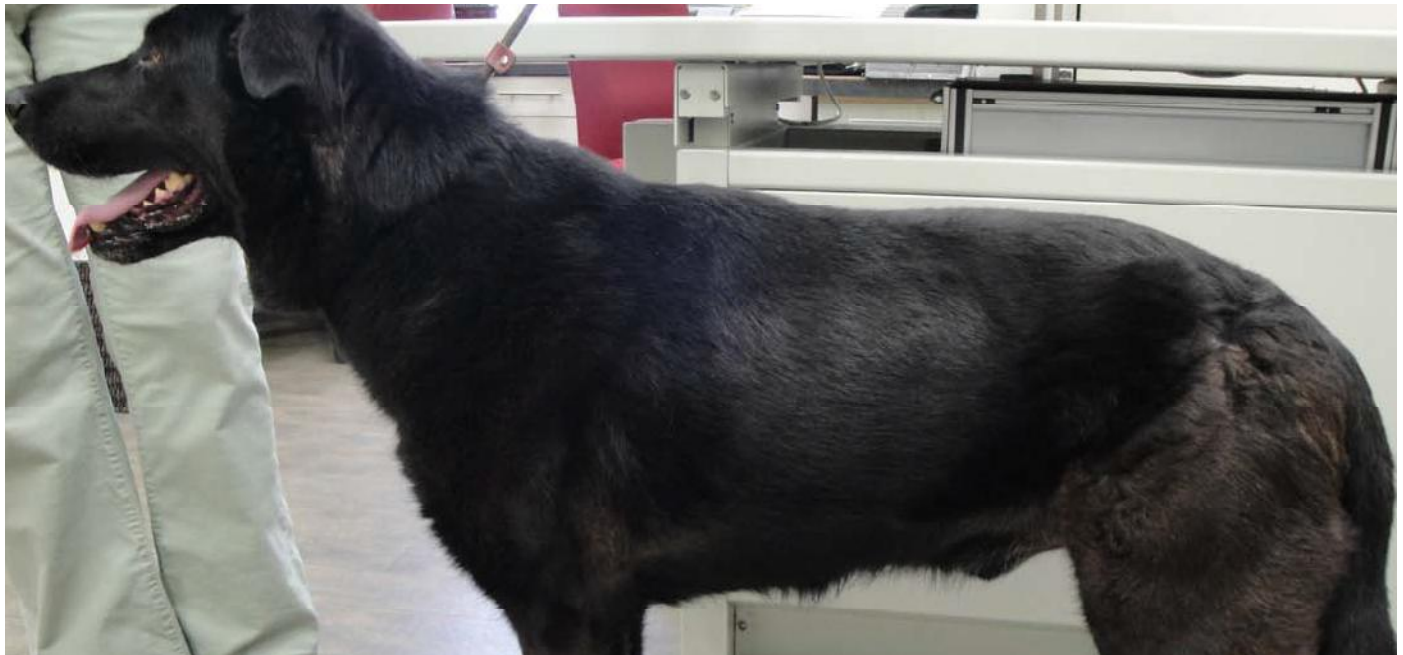

Figure 6 - Day 132 (final assessment).

the patient was feeling good and moving normally on long walks. Treatment with the G, H, I protocol was continued at one week intervals.

Day - 55: All the skin edges were firmly adhered.

Day - 62: The wound continued to contract and the muscle surface looked very healthy (**Figure 4**). The wound measured 5.5 cm by 5.5 cm.

Day - 79: The last (26th) laser therapy session was performed. The wound had healthy granulation tissue and was very small (3.5 cm by 3 cm).

Day - 132: Final assessment. The wound had healed. All that remained was a 3 cm area of pigmented, sparsely haired skin with a 1.5 cm diameter non-pigmented, scaly alopecic area on the caudal edge (**Figures 5 and 6**).

Discussion


The patient's severe non-healing wound of unknown origin failed to respond to conventional therapy consisting of surgery and medications. Each treatment designed to elicit healing, including attempts at partial closure of the defect, was unsuccessful. The infection was controlled intermittently with antibiotic combinations but always recurred. A culture was not done due to client finances, but might have provided insight into bacterial resistance.

The initial strategy for wound management was abandoned when the patient was on the verge of being euthanized for humane reasons. He had spiraled down in condition, hardly eating, lacking energy, with a weight loss of 4.5 kg, and had developed epistaxis. The decision to utilize FSLLL therapy was based on prior personal experience with its use, but also backed up by proven efficacy in wound repair (1).

Once all conventional therapy with the exception of meloxicam was discontinued and laser therapy was initiated, the dog's attitude improved. He had more energy, more interest in things around him, and ate better than he had in weeks.

More importantly, the wound became cleaner with less evidence of infection daily. The wound steadily healed by

contracture until it resolved to a small area of scar tissue. The advantage of FSLLL therapy and the Erchonia laser is that it cannot do harm. It effectively stimulates wound healing and, according to Inman (2), the choice of the correct frequencies can boost the immune system's ability to eradicate infection. For example, the 111 frequency addresses scar tissue while 279 treats inflammatory pockets. FSLLL can be used in this way, in a directed therapy method, or it can be used in a general way to reduce pain, inflammation, and irritation, which lessens the chance of further excoriation.

This case report documents the positive effect of FSLLL therapy on a severe non-healing wound in a canine patient. Further investigation is needed into the efficacy of FSLLL therapy on wounds and other disease processes in animals. 

ENDNOTES:

- a) The two medications used (Amoxicillin and Ibuprofen) were assumed to be generic versions of these medications.
- b) Zeniquin, Pfizer Animal Health, Kirkland, Quebec, Canada
- c) Tramadol, Summit Veterinary Pharmacy Inc, Aurora, Ontario, Canada
- d) Metacam, Boehringer Ingelheim, Burlington, Ontario, Canada
- e) Metronidazole, AA Pharma Inc, Toronto, Ontario, Canada
- f) Apo-sulfatrim, Apotex Inc, Toronto, Ontario, Canada
- g) Braunamid, Aesculop Ag & Co, Tuttlingen, Germany
- h) True North Veterinary Diagnostics, Burnaby, BC, Canada

REFERENCES:

1. Equine wound healing: influence of low level laser therapy on an equine metacarpal wound healing model. Henry W. Jann, Kenneth Bartels, Jerry W. Ritchey, Mark Payton, and John M. Bennett, Photon Lasers Med 1 (2012): 117-122 © 2012 by Walter de Gruyter • Berlin • Boston. Available at: "http://www.erchonia.com/files/uploads/1/file/Jann_Equine%20Wound%20Healing%20Influence%20LLLT%20Metacarpal%20Wound%20Healing_Photon%20Lasers_Med_05_12.pdf"
2. Inman, personal communication