

# Equine wound healing: influence of low level laser therapy on an equine metacarpal wound healing model

## Wundheilung beim Pferd: Untersuchungen zur Wirksamkeit der Low-Level-Laser-Therapie am Wundheilungsmodell (Mittelfußregion)

Henry W. Jann<sup>1,\*</sup>, Kenneth Bartels<sup>1</sup>,  
Jerry W. Ritchey<sup>2</sup>, Mark Payton<sup>3</sup> and  
John M. Bennett<sup>1</sup>

<sup>1</sup>Department of Veterinary Clinical Sciences, Center for Veterinary Health Sciences, Oklahoma State University, 002 BVMTH, Stillwater, OK 74078, USA, e-mail: henry.jann@okstate.edu

<sup>2</sup>Department of Veterinary Pathobiology, Center for Veterinary Health Sciences, Oklahoma State University, 250 McElroy Hall, Stillwater, OK 74078, USA

<sup>3</sup>Statistics Department, Oklahoma State University, MSCS 301, Stillwater, OK 74078, USA

\*Corresponding author

### Abstract

**Objective:** To evaluate the effects of low level laser therapy (LLLT) on healing of full thickness symmetrical skin wounds in horses. LLLT is a therapeutic modality using the application of light, usually a low power laser or light emitting diode in the power range of 1 mW to 12 W that, in practical terms, promotes tissue regeneration as well as reducing inflammation and pain.

**Study design:** Experimental study.

**Animals:** Healthy horses (n=8).

**Methods:** Full thickness, 2.5 cm square skin wounds were created in the mid-metacarpal region on one leg of eight normal horses. LLLT was used on limbs assigned to the experimental group and limbs assigned to the control group were allowed to heal without treatment. LLLT was administered using a line generated optical scanner with a dual diode laser system (model EML; Erchonia Laser Healthcare, McKinney, TX, USA) at a wavelength of 635 nm and an energy output of 17 mW per diode. Wound size was measured for an 80-day period post operatively. Eighty days after surgery incisional biopsies were examined histologically.

**Results:** Wounds treated with LLLT healed faster than the control wounds ( $p=0.01$ ). Wounds treated with LLLT were completely epithelialized at day 80 after surgery. Control wounds were not epithelialized at postoperative day 80.

**Conclusion:** LLLT increased the rate of wound healing.

**Keywords:** wounds; wound healing; metacarpal; LLLT; epithelialization.

### Zusammenfassung

**Zielsetzung:** Evaluation der Wirksamkeit der Low-Level-Laser-Therapie (LLLT) auf die Heilung symmetrischer Hautwunden (Vollhaut) bei Pferden. Bei der LLLT wird Licht, üblicherweise von Low-Power-Lasern oder LEDs im Leistungsbereich von 1 mW bis 12 W, appliziert, resultierend in einer verbesserten Geweberegeneration, Entzündungshemmung und Schmerzlinderung.

**Studiendesign:** Experimentelle Studie.

**Tiere:** Gesunde Pferde (n=8).

**Methoden:** Im Mittelfußbereich jeweils eines Beins von 8 gesunden Pferden wurden 2,5×2,5 cm<sup>2</sup> große Hautwunden (Vollhaut) chirurgisch erzeugt und entweder mittels LLLT behandelt (Experimentalgruppe) oder keiner speziellen Therapie unterzogen (Kontrollgruppe). Für die LLLT kam ein optischer Laserscanner der Fa. Erchonia Laser Healthcare (Modell EML, duales Laserdiodensystem; Wellenlänge: 635 nm, Leistung: 17 mW pro Laserdiode) zum Einsatz.

Die Wundgröße wurde post-operativ über einen Zeitraum von 80 Tagen vermessen. Mit Ende des Kontrollzeitraums, 80 Tage nach dem chirurgischen Eingriff, wurden Gewebeproben (Inzisionsbiopsie) entnommen und histologisch untersucht.

**Ergebnisse:** Die Hautwunden, die mit LLLT behandelt wurden, heilten schneller als die unbehandelten Wunden aus der Kontrollgruppe ( $p=0.01$ ). 80 Tage nach dem chirurgischen Eingriff waren alle mittels LLLT behandelten Wunden vollständig epithelialisiert. Dies war in der Kontrollgruppe nicht der Fall.

**Zusammenfassung:** Eine Behandlung mittels LLLT verbessert die Wundheilungsrate.

**Schlüsselwörter:** Wunden; Wundheilung; Mittelfußbereich; Low-Level-Laser-Therapie (LLLT); Epithelisierung.

### 1. Introduction

Low level laser therapy (LLLT) is a therapeutic modality using the application of light, usually a low power laser or light emitting diode in the power range of 1 mW to 12 W that in practical terms promotes tissue regeneration as well as reducing inflammation and pain. LLLT can be defined using several parameters that include power, wavelength,

pulse rate and duration, total irradiation time, intensity ( $\text{W}/\text{cm}^2$ ), and dose ( $\text{J}/\text{cm}^2$ ). Classifications of lasers, designated by the American National Standards Institute, used for LLLT range from Class 2 through 4. Conceptually, LLLT is not considered a photothermal activity but in practice – using some Class 3B and 4 devices – photothermal activity (not including tissue ablation) may occur to a limited extent. The basic mechanism, as defined for LLLT, is considered photochemical or tissue activity through photobiomodulation or photobiostimulation [1, 2]. This study utilizes a Class 3B LLLT device to enhance wound healing in the equine wound model.

Wound healing in the distal limbs of horses is an aspect of veterinary medicine that has made few advances in spite of our expanding knowledge and technological progress. In fact, treating distal leg wounds (DLWs) and the ensuing exuberant granulation tissue remains one of the most frustrating clinical challenges [3]. There have been countless topical preparations and medications that have been applied to DLWs over the millennia and even in recent times, but few have actually been scientifically shown to possess significant clinical efficacy. There have been numerous studies comparing treatments such as corticosteroids [4], platelet rich plasma [5], occlusive dressings [6], and collagen gel [7], growth factors [8] and immobilization [9], but no treatment has been shown to have a statistically significant effect on the healing rate of full thickness excisional skin wounds. The goals of treating DLWs include minimizing exuberant granulation tissue and facilitating contraction and epithelialization. Minimizing scar tissue and adhesion of underlying deep structures are also important considerations [10].

LLLT has been shown to be beneficial in facilitating healing of slow or non-healing wounds in laboratory animals [11] and humans [12–15]. LLLT stimulates cellular physiologic processes [16]. Near-infrared light stimulates cytochrome c oxidase located within the mitochondrial respiratory chain [17–19]. This causes up-regulation of oxidative phosphorylation and increased production of adenosine triphosphate (ATP) [20, 21]. Increased ATP availability augments intracellular and extracellular signaling resulting in pain and edema reduction [22–24]. Efficacy of LLLT in wound healing, control of inflammation, and pain management has also been documented [25, 26]. The physiological effect of LLLT is one of direct stimulation of tissue without thermal vaporization. A visible light is emitted with a wavelength of 630–640 nm that easily passes through dermal tissue [23, 27]. Documented effects of LLLT include increased production of growth factors, cellular matrix, angiogenesis, and cytokine release [28, 29]. Other events critical to wound healing that occur between 630 and 640 nm include activation of fibroblasts and keratocytes, DNA replication, cellular proliferation, and angiogenesis [30–32]. This experiment attempted to document the effects of LLLT (635 nm wavelength red laser light) on the healing characteristics of surgically created identical and symmetrical DLWs in a controlled environment.

## 2. Materials and methods

### 2.1. Horses

Eight mature mares were studied. Age range was 5–12 years and weight range was 464–615 kg.

### 2.2. Surgical procedure and LLLT treatment

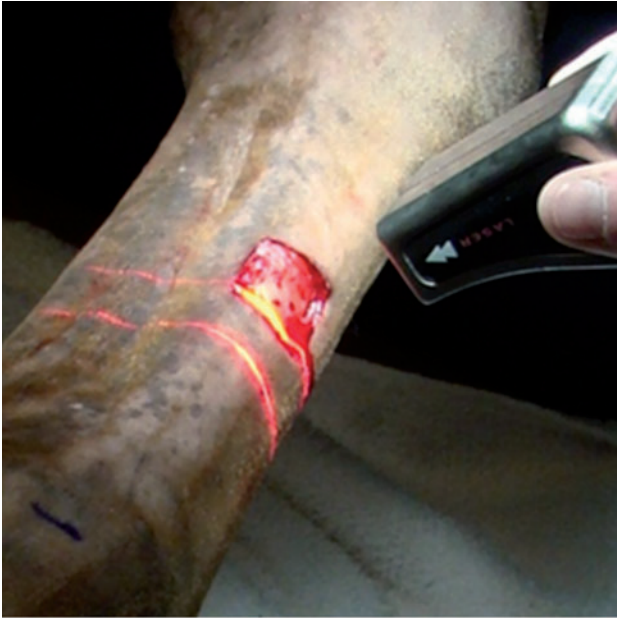Treatment protocols of the animals in this project were approved by the Institutional Animal Care and Use Committee. Application of the low level ANSI Class 3B medical laser for this project was utilized in accordance with ANSI Z136.3 guideline “American National Standard for Safe Use of Lasers in Health Care” (2005).

After induction and maintenance of general anesthesia, DLWs were created on limbs of eight mature horses. A unilateral full thickness 2.5 cm square excisional skin wound was created on the dorsal mid-metacarpal region equidistant from the carpometacarpal and metacarpophalangeal joints of each horse. The wounds were created with a #10 scalpel blade after tracing the outline with a stencil (Figure 1). Hemostasis was obtained with electrosurgical coagulation and all legs were bandaged for five days after surgery. Post-operative analgesia was provided with flunixin meglumine (1.1 mg/kg at 12 h) for three days.

A randomized experimental design was used so that an equal number of right and left legs were used for both control and experimental data points. LLLT was applied to the experimental wounds every other day for 80 days. The laser beam target area was determined by manually maintaining the optical scanner approximately 3 cm from the wound area and irradiating a 4 cm<sup>2</sup> area (linear beam size) directly over the wound site (Figure 2). LLLT was administered using a line generated optical scanner with a dual diode laser system (model EML; Erchonia Laser Healthcare, McKinney, TX, USA) at a wavelength of 635 nm and an energy output of 17 mW per diode. Laser therapy was initiated and applied at the wound site for 5 min with pre-set pulsed laser therapy frequencies alternating from 28, 16, 12, to 4 Hz, with a 50% duty cycle from each diode, i.e., as the laser is a dual diode system one diode will pulse 28 and 16 Hz rotating frequencies every second and the other diode would pulse at 12 and 4 Hz.



**Figure 1** 2.5×2.5 cm<sup>2</sup> full-thickness skin wound.



**Figure 2** LLLT of metacarpal wound using a dual-diode, line generated optical scanner (model EML; Erchonia Laser Healthcare, McKinney, TX, USA).

These energy parameters were established according to the manufacturer's specifications. Total energy delivered to the wound was 5.1 J/cm<sup>2</sup> per treatment.

In conjunction with direct wound treatment, irradiation/LLLT of the associated nerves proximal to the wound site (median/musculocutaneous nerves as they exited the brachial plexus) was also performed. The same optical scanner and dual diode laser system used for wound treatment was also employed for this aspect of the protocol. The scanner was held in contact or within 1 cm of the skin over the nerve trunks as they coursed distally to the area of the wound site. Laser beam size for this aspect of the LLLT was 1 cm<sup>2</sup>. Pulsed laser delivery frequencies were set at alternating frequencies from 9, 16, 33, to 60 Hz. Total irradiation time was 3 min for total energy delivery to the "trigger point" of 1.6 J/cm<sup>2</sup> per treatment.

Wound size area was assessed digitally using ImageJ software (ImageJ 1.44p; National Institutes of Health, Bethesda, MD, USA). The wound size was calculated and wound healing curves were generated. Control curves were compared to experimental curves and a statistical analysis was obtained.

### 2.3. Statistical analysis

All statistical analyses were conducted with PC SAS Version 9.2 (SAS Institute, Cary, NC, USA). Analysis of variance procedures assuming a repeated measures model were utilized to ascertain the effects of treatment, time and the treatment by time interaction. An autoregressive analysis with time period 1 covariance structure was used to model the intra-horse variation over time. The analysis focused on wound data measured after day 26. The interaction of treatment by time was assessed, and if not significant, main effects of time

and treatment evaluated. All tests were considered significant if  $p < 0.05$ .

## 3. Results

### 3.1. Rate of wound healing

The time by treatment interaction was not significant ( $p = 0.9802$ ), which enabled us to evaluate the main effect of treatment (averaged over time). The effect of treatment averaged over time was significant (control mean = 0.25 vs. treatment mean = 0.15;  $p = 0.0134$ ). There was a steady decrease in wound size for both control and experimental wounds after day seven. The rate of healing was statistically different for the control and experimental (LLLT) wounds after day 17 (Figure 3). Experimental wounds were fully contracted and epithelialized by day 80 (Figure 4B). Control wounds were approximately 9% larger and not fully epithelialized (Figure 4A). The time for complete epithelialization of the control wounds was not determined because the study ended with the biopsy procedure. The fastest rate of decrease in wound size was between day 19 and day 46 for both control and experimental wounds. During this time period the slope of the wound healing lines was the steepest.

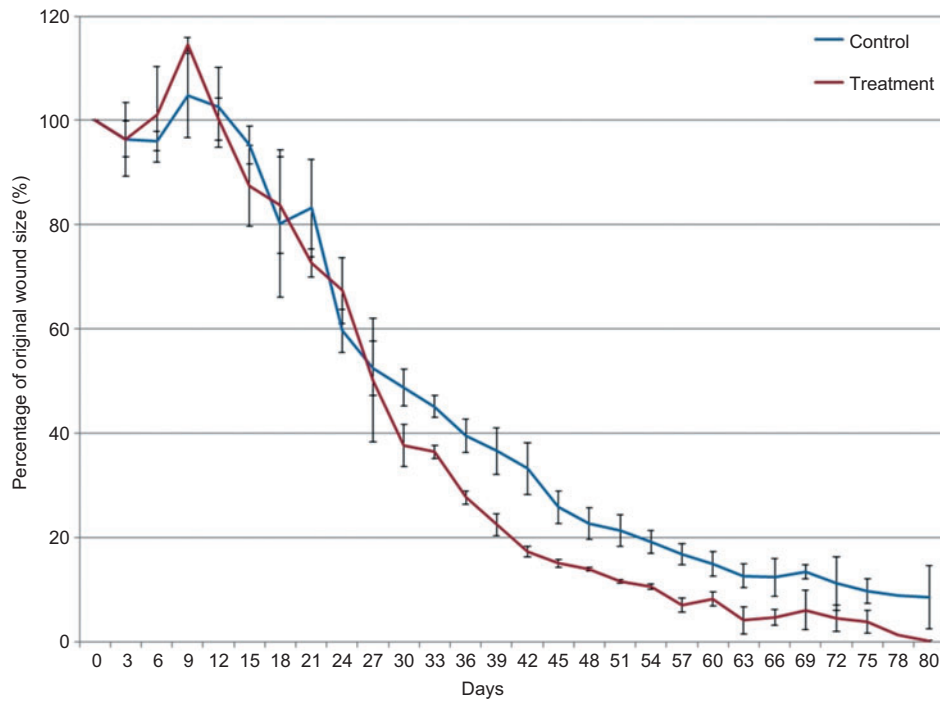
### 3.2. Histologic evaluation

The wound site dermis of both control and laser-treated horses was expanded and effaced by deposition of densely cellular and highly vascular granulation tissue. The granulation tissue was abruptly demarcated from the adjacent dermis at the margin of the wound. All control animals exhibited ulceration of the wound site with the exposed granulation bed covered by a thick serocellular crust comprised of an admixture of fibrin, serum protein and intact and degenerate neutrophils. The immediate underlying granulation tissue was heavily infiltrated by primarily neutrophilic inflammatory cells. The epithelium at the margins of the ulcer was markedly hyperplastic with formation of deep, irregular pegs. Some animals exhibited sliding of isolated nests of hyperplastic epithelial cells across the ulcer bed; however, these were always discontinuous. In contrast, all treated horses exhibited intact epithelial surfaces. The granulation bed was completely covered by evenly hyperplastic epithelium with orthokeratotic hyperkeratosis. Some animals exhibited hemorrhage within the granulation region, but this was always mild. Inflammation was minimal and restricted to few, scattered mononuclear cells within the granulation bed (Figure 5A,B).

## 4. Discussion

The rate of healing of non-treated wounds was consistent with previous reported data for horse wounds [10]. These results of this study are similar to a previously reported study investigating the use of extracorporeal shock wave therapy in which a similar model and wound measurement methodology was used [33]. The laser-treated wounds had a more advanced rate

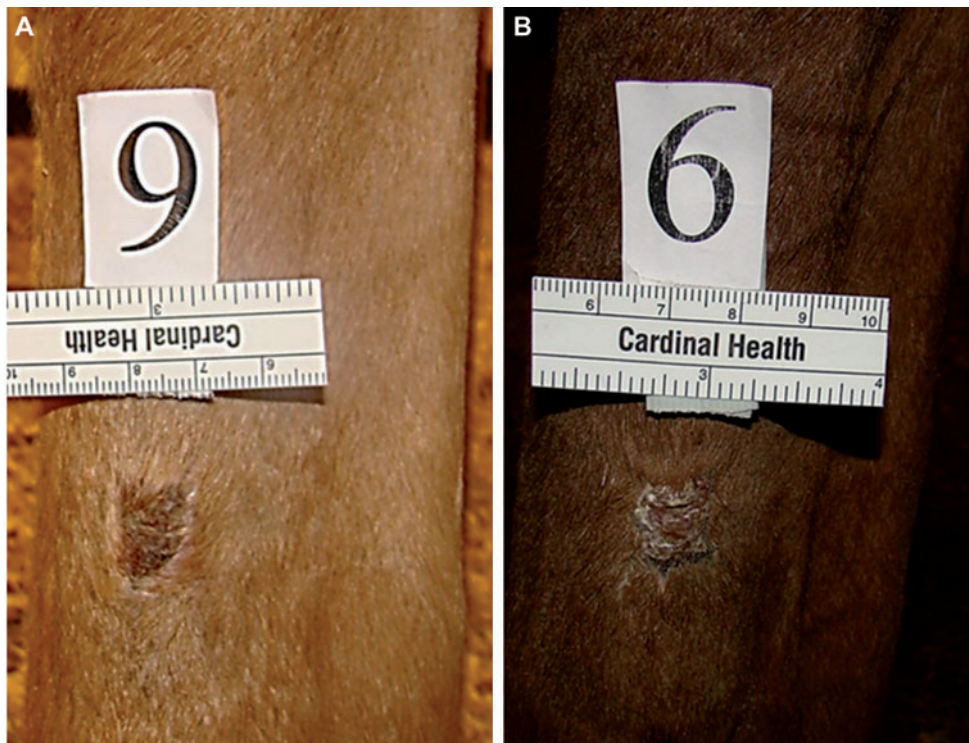



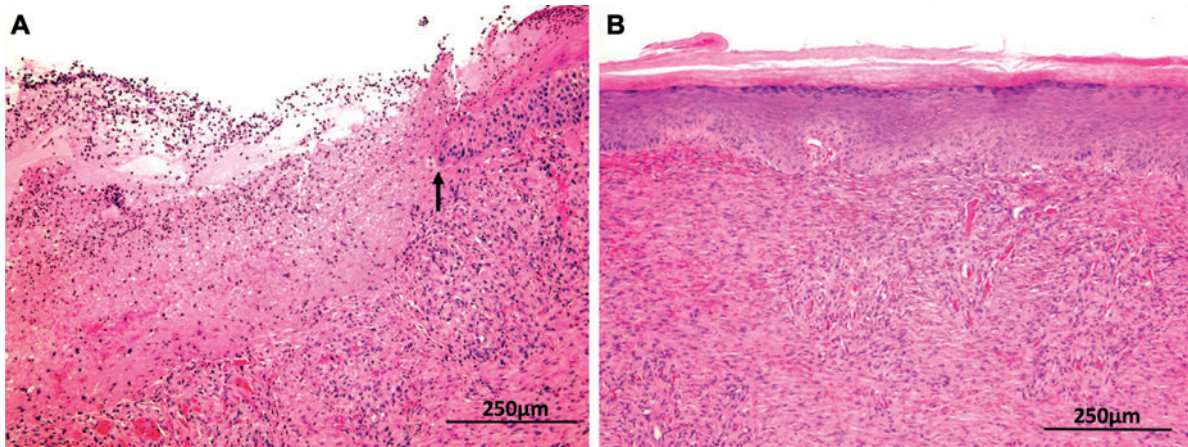
**Figure 3** Final graph of mean percentage of wound size vs. time (days) for control and laser-treated (LLLT) wounds.

of healing than non-treated wounds in this study and previously reported healing rates [10]. Our clinical impression was that the laser-treated wounds healed primarily by wound contraction in the manner previously reported for pony wounds

[10]. A significant clinical observation was the absence of exuberant granulation tissue in the laser-treated wounds. The wound margins of the laser-treated wounds contracted and epithelialized and the overall contour of the wounds



**Figure 4** Appearance of (A) control and (B) laser-treated wounds at day 80.



**Figure 5** Horse, skin. Hematoxylin and eosin stains. (A) Control horse skin exhibited ulcers over the granulation bed at the wound site. The ulcers were covered by serocellular crusts with epithelial hyperplasia at the margins (arrow). The underlying granulation bed was inflamed (neutrophilic). (B) The granulation bed at the wound site from treated horses was completely covered by evenly hyperplastic epithelium with orthokeratotic hyperkeratosis. Inflammation was minimal and characterized by few, evenly scattered macrophages and lymphocytes within the granulation bed.

remained flat and parallel to the surrounding epithelium. This is potentially clinically relevant because control of exuberant granulation tissue is a pivotal factor in management of equine wounds located in the distal limb.

LLLT of the metacarpal wounds included direct wound treatment as specified, as well as LLLT of the associated nerves proximal to the wounds site. In this study, the LLLT device employed for direct wound treatment was also used for irradiation of the median/musculocutaneous nerves proximal to the wound site. Direct and nerve root irradiation as well as treatment of “trigger points,” are frequently discussed in relation to complementary medicine techniques, namely “laser acupuncture”. A complete discussion of that topic is beyond the scope of this paper. However, previous work has shown that both pain relief and enhanced wound healing can be initiated using direct and indirect LLLT effects on cellular activity. Direct cellular activation is postulated to lead to indirect activation of distant cells via secondary messengers (reactive oxygen species, lymphokines, cytokines, nitric oxide, and calcium) released by directly activated cells [12, 34, 35]. In this study, it was not possible to ascertain whether treatment of the nerves proximal to the wound site enhanced wound healing or alleviated potential discomfort at the wound site.

## 5. Conclusion

LLLT had a positive effect on healing rate and healing characteristics of DLWs in horses.

## Acknowledgements

The authors would like to thank Jennifer Sisk-Miley, RVT, Chase Whitfield, DVM, Sarah Urban, Amber Burton, DVM, and Troye Myers, DVM for their technical assistance.

## References

- [1] Huang YY, Chen AC, Carroll JD, Hamblin MR. Biphasic dose response in low level light therapy. *Dose Response* 2009;7(4):358–83.
- [2] Posten W, Wrone DA, Dover JS, Arndt KA, Silapunt S, Alam M. Low-level laser therapy for wound healing: Mechanism and efficacy. *Dermatol Surg* 2005;31(3):334–40.
- [3] Wilmink JM, van Weeren PR. Second-intention repair in the horse and pony and management of exuberant granulation tissue. *Vet Clin North Am Equine Pract* 2005;21(1):15–32.
- [4] Hashimoto I, Nakanishi H, Shono Y, Toda M, Tsuda H, Arase S. Angiostatic effects of corticosteroid on wound healing of the rabbit ear. *J Med Invest* 2002;49(1–2):61–6.
- [5] Monteiro SO, Lepage OM, Theoret CL. Effects of platelet-rich plasma on the repair of wounds on the distal aspect of the forelimb in horses. *Am J Vet Res* 2009;70(2):277–82.
- [6] Howard RD, Stashak TS, Baxter GM. Evaluation of occlusive dressings for management of full-thickness excisional wounds on the distal portion of the limbs of horses. *Am J Vet Res* 1993;54(12):2150–4.
- [7] Bertone AL, Sullins KE, Stashak TS, Norrdin RW. Effect of wound location and the use of topical collagen gel on exuberant granulation tissue formation and wound healing in the horse and pony. *Am J Vet Res* 1985;46(7):1438–44.
- [8] Steel CM, Robertson ID, Thomas J, Yovich JV. Effect of topical rh-TGF-beta 1 on second intention wound healing in horses. *Aust Vet J* 1999;77(11):734–7.
- [9] Fretz PB, Martin GS, Jacobs KA, McIlwraith CW. Treatment of exuberant granulation tissue in the horse: evaluation of four methods. *Vet Surg* 1983;12(3):137–40.
- [10] Wilmink JM, van Weeren PR. Differences in wound healing between horses and ponies: application of research results to the clinical approach of equine wounds. *Clin Tech Eq Pract* 2004;3(2):123–33.
- [11] Demidova-Rice TN, Salomatina EV, Yaroslavsky AN, Herman IM, Hamblin MR. Low-level light stimulates excisional wound healing in mice. *Lasers Surg Med* 2007;39(9):706–15.

- [12] Karu TI. Low-power laser therapy. In: Vo-Dinh T, editor. *Biomedical photonics handbook*. Boca Raton: CRC Press; 2003, p. 48-1-20.
- [13] Medrado AR, Pugliese LS, Reis SR, Andrade ZA. Influence of low level laser therapy on wound healing and its biological action upon myofibroblasts. *Lasers Surg Med* 2003;32(3):239-44.
- [14] Posten W, Wrone DA, Dover JS, Arndt KA, Silapunt S, Alam M. Low-level laser therapy for wound healing: mechanism and efficacy. *Dermatol Surg* 2005;31(3):334-40.
- [15] Jackson RF, Roche G, Mangione T. Low-level laser therapy effectiveness for reducing pain after breast augmentation. *Am J Cosmet Surg* 2009;26(3):1-5.
- [16] Al-Watban FA, Zhang XY. The comparison of effects between pulsed and cw lasers on wound healing. *J Clin Laser Med Surg* 2004;22(1):15-8.
- [17] Karu T, Pyatibrat L, Kalendo G. Irradiation with He-Ne laser increases ATP level in cells cultivated in vitro. *J Photochem Photobiol B* 1995;27(3):219-23.
- [18] Afanasyeva NI, Karu TI, Tiflova OA. Oxidases bd and bo as primary photoacceptors during exposure to low intensity visible monochromatic irradiation of *Escherichia coli* cells. *Dokl Akad Nauk* 1995;345(3):404-6.
- [19] Pastore D, Greco M, Passarella S. Specific helium-neon laser sensitivity of the purified cytochrome c oxidase. *Int J Radiat Biol* 2000;76(6):863-70.
- [20] Wong-Riley MT, Bai X, Buchmann E, Whelan HT. Light-emitting diode treatment reverses the effect of TTX on cytochrome oxidase in neurons. *Neuroreport* 2001;12(14):3033-7.
- [21] Wong-Riley MT, Liang HL, Eells JT, Chance B, Henry MM, Buchmann E, Kane M, Whelan HT. Photobiomodulation directly benefits primary neurons functionally inactivated by toxins: role of cytochrome c oxidase. *J Biol Chem* 2005;280(6):4761-71.
- [22] Eells JT, Henry MM, Summerfelt P, Wong-Riley MT, Buchmann EV, Kane M, Whelan NT, Whelan HT. Therapeutic photobiomodulation for methanol-induced retinal toxicity. *Proc Natl Acad Sci USA* 2003;100(6):3439-44.
- [23] Eells JT, Wong-Riley MT, VerHoeve J, Henry M, Buchman EV, Kane MP, Gould LJ, Das R, Jett M, Hodgson BD, Margolis D, Whelan HT. Mitochondrial signal transduction in accelerated wound and retinal healing by near-infrared light therapy. *Mitochondrion* 2004;4(5-6):559-67.
- [24] Karu TI, Pyatibrat LV, Kolyakov SF, Afanasyeva NI. Absorption measurements of a cell monolayer relevant to phototherapy: reduction of cytochrome c oxidase under near IR radiation. *J Photochem Photobiol B* 2005;81(2):98-106.
- [25] Enwemeka CS, Parker JC, Dowdy DS, Harkness EE, Sanford LE, Woodruff LD. The efficacy of low-power lasers in tissue repair and pain control: a meta-analysis study. *Photomed Laser Surg* 2004;22(4):323-9.
- [26] Naeser MA. Photobiomodulation of pain in carpal tunnel syndrome: review of seven laser therapy studies. *Photomed Laser Surg* 2006;24(2):101-10.
- [27] Bortoletto R, Silva NS, Zângaro RA, Pacheco MT, Da Matta RA, Pacheco-Soares C. Mitochondrial membrane potential after low-power laser irradiation. *Lasers Med Sci* 2004;18(4):204-6.
- [28] Burd A, Zhu N, Poon VK. A study of Q-switched Nd:YAG laser irradiation and paracrine function in human skin cells. *Photodermatol Photoimmunol Photomed* 2005;21(3):131-7.
- [29] Maiya GA, Kumar P, Rao L. Effect of low intensity helium-neon (He-Ne) laser irradiation on diabetic wound healing dynamics. *Photomed Laser Surg* 2005;23(2):187-90.
- [30] Gavish L, Perez L, Gertz SD. Low-level laser irradiation modulates matrix metalloproteinase activity and gene expression in porcine aortic smooth muscle cells. *Lasers Surg Med* 2006;38(8):779-86.
- [31] Dvoretzki DP, Timoshenko TE, Belobokova NK. Effect of low-intensity He-Ne laser irradiation on rat mesenteric microcirculation. *Russ Fiziol Zh Im I M Sechenova* 2004;90(11):1356-62.
- [32] van Breugel HH, Bär PR. Power density and exposure time of He-Ne laser irradiation are more important than total energy dose in photo-biomodulation of human fibroblasts in vitro. *Lasers Surg Med* 1992;12(5):528-37.
- [33] Morgan DD, McClure S, Yaeger MJ, Schumacher J, Evans RB. Effects of extracorporeal shock wave therapy on wounds of the distal portion of the limbs in horses. *J Am Vet Med Assoc* 2009;234(9):1154-61.
- [34] Simunovic Z, Ivankovich AD, Depolo A. Wound healing of animal and human body sport and traffic accident injuries using low-level laser therapy treatment: a randomized clinical study of seventy-four patients with control group. *J Clin Laser Med Surg* 2000;18(2):67-73.
- [35] Baratto L, Calzà L, Capra R, Gallamini M, Giardino L, Giuliani A, Lorenzini L, Traverso S. Ultra-low-level laser therapy. *Lasers Med Sci* 2011;26(1):103-12.

Received January 24, 2012; revised March 1, 2012; accepted March 7, 2012