

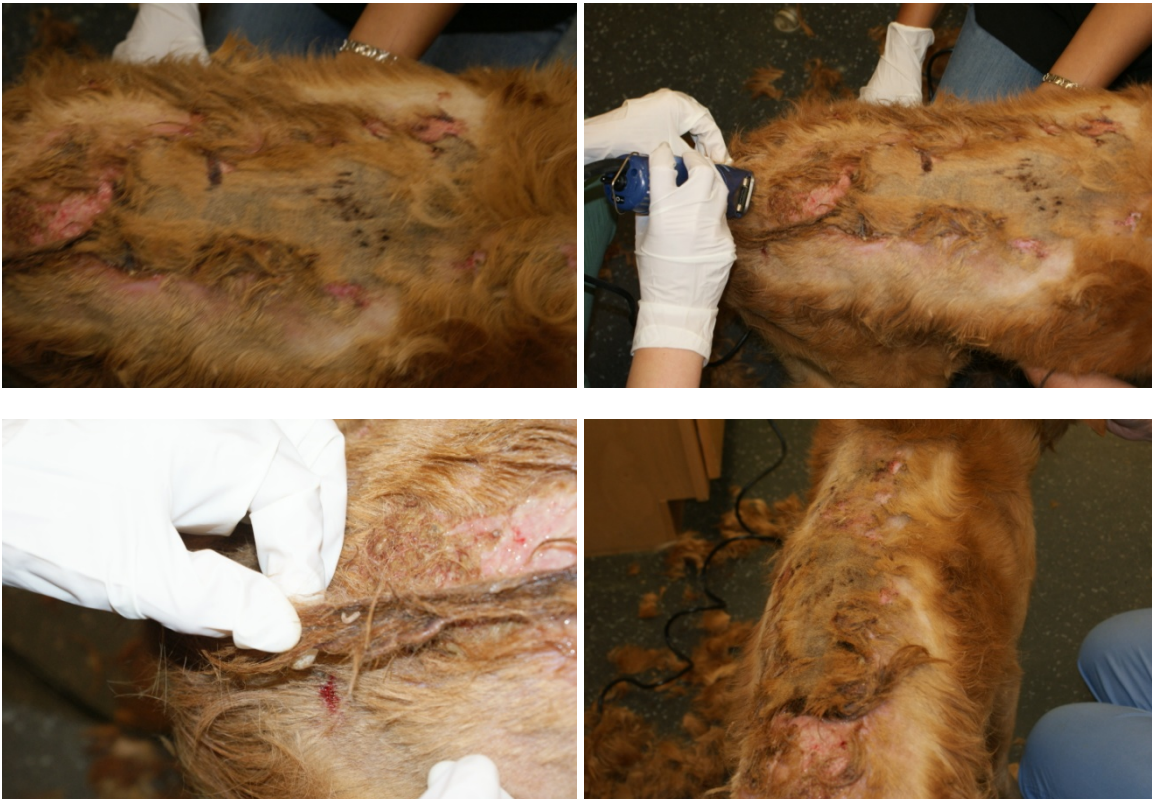## Erchonia Laser Case Study – Wound

Dave Huff, DVM  
Clayton, NC

“Bucky” is a 4 year old Golden Mix, 74 pounds.

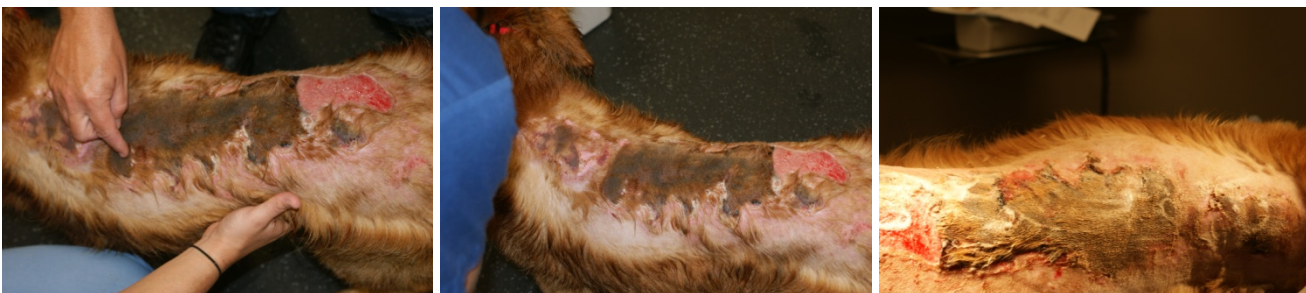Presented 8/15 for lethargy, and skin infection, examination revealed sloughing and necrosis of an area approximately 18 inches by 6 inches, extending from the scapula to the tail head. Possible spider bite, drug reaction (no known exposures), diagnosis severe necrotizing dermatitis with maggot invasion.

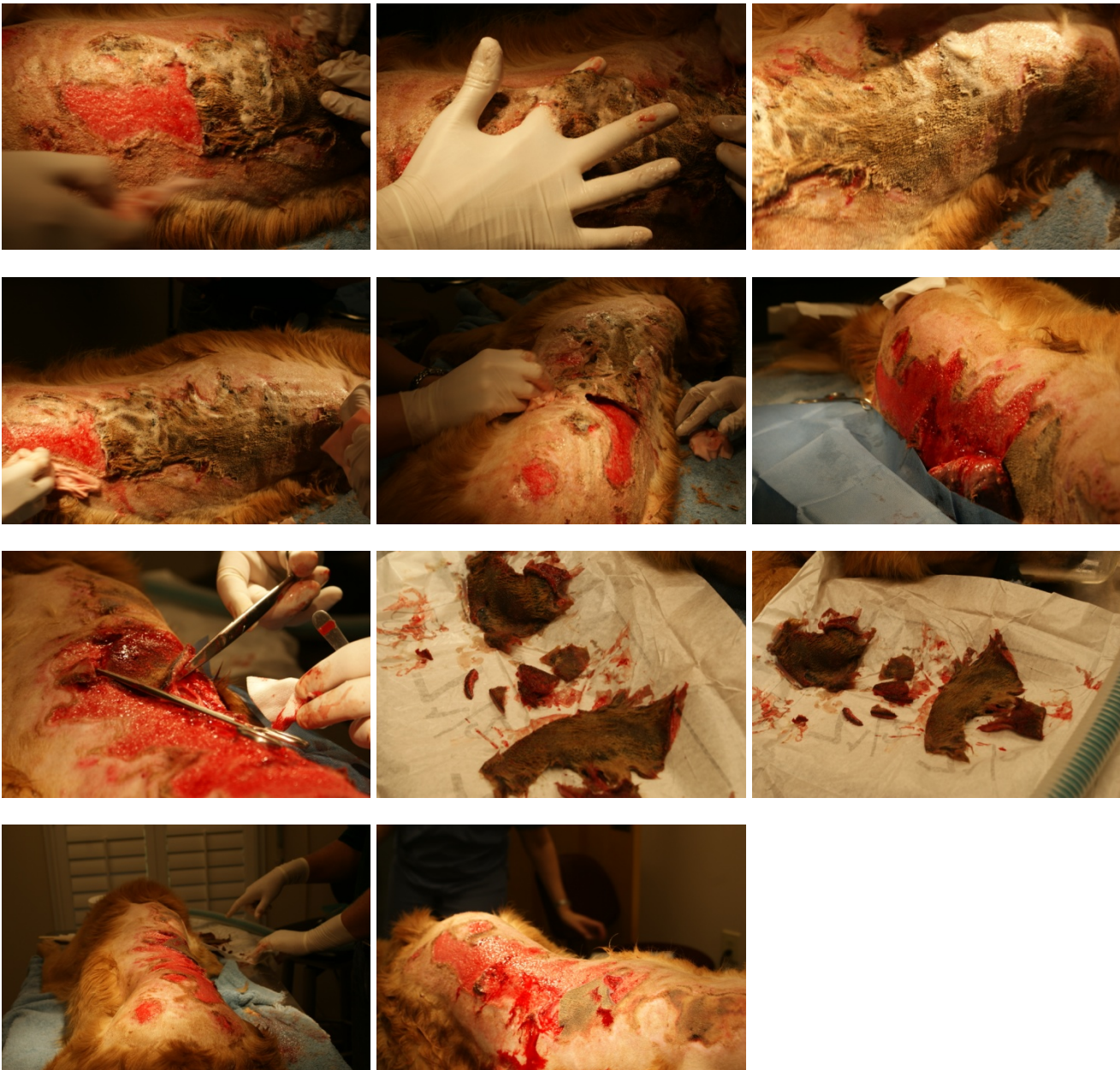### Initial Presentation



Surgical debridement and cleaning was then performed, to remove necrotic tissues, gas producing bacteria were present with multiple pockets of dead tissue.

### Photos During and After Surgery





Wound care began with low level laser therapy twice daily for 3 days. Silver Sulfadiazine topically applied and oral antibiotics (Cephalexin 500mg TID).

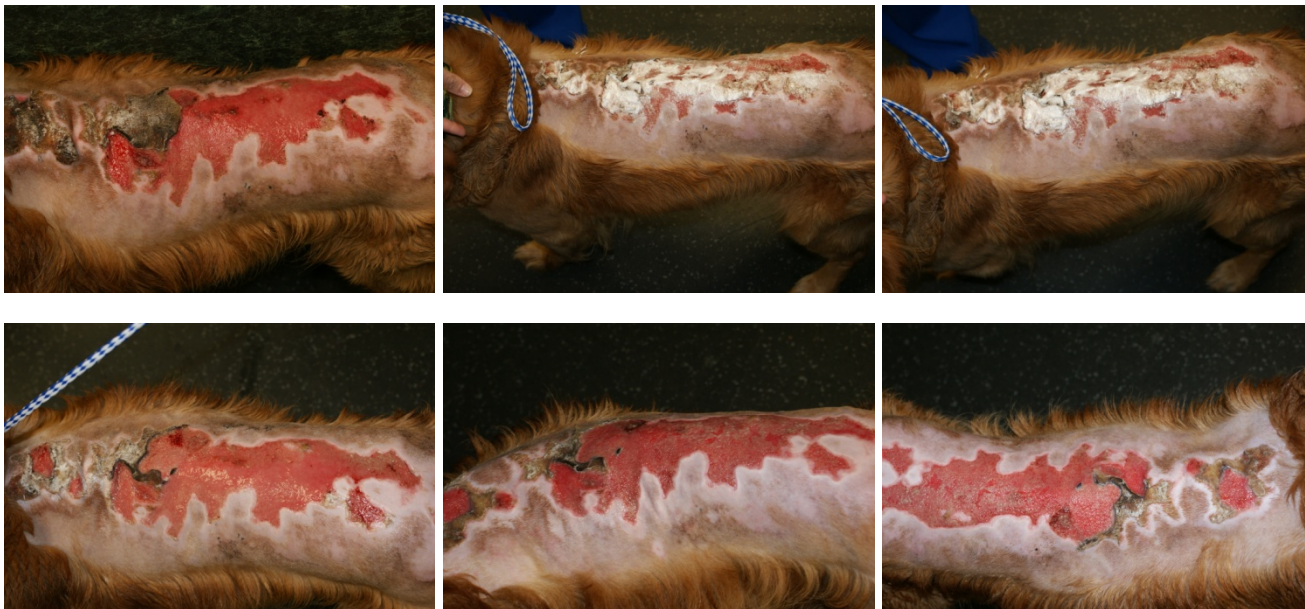3LT settings were as follows:

- 40/190/444/1865 x 180 sec preset @AOI
- 363/784/465/73 x 180 sec preset @AOI
- 25/100/52/4 x 180 sec preset @AOI

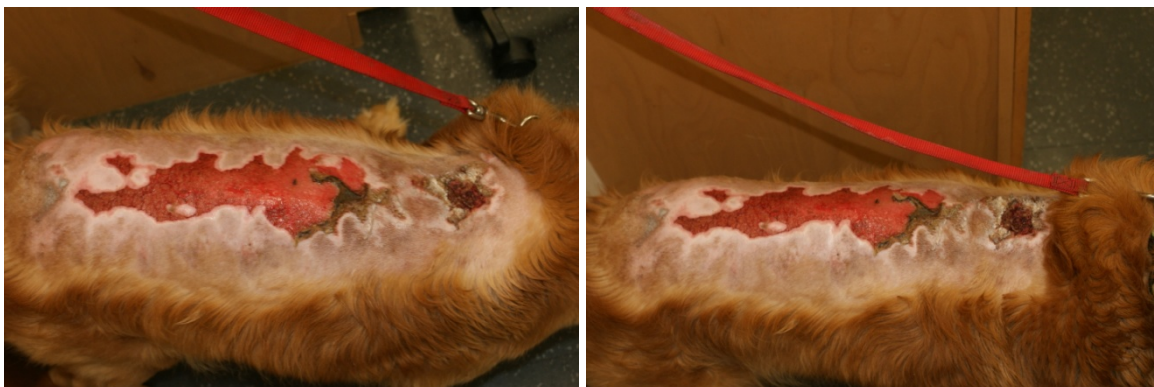

7 days post surgery 8/22/11

Continued 3LT at weekly intervals to monthly. 13 total treatments over next 90 days.



10 Days Post Surgery

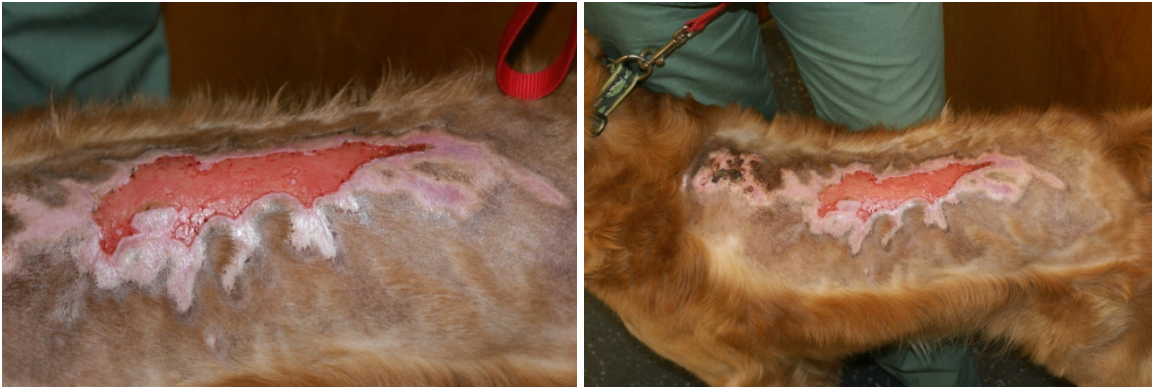

14 Days Post Surgery

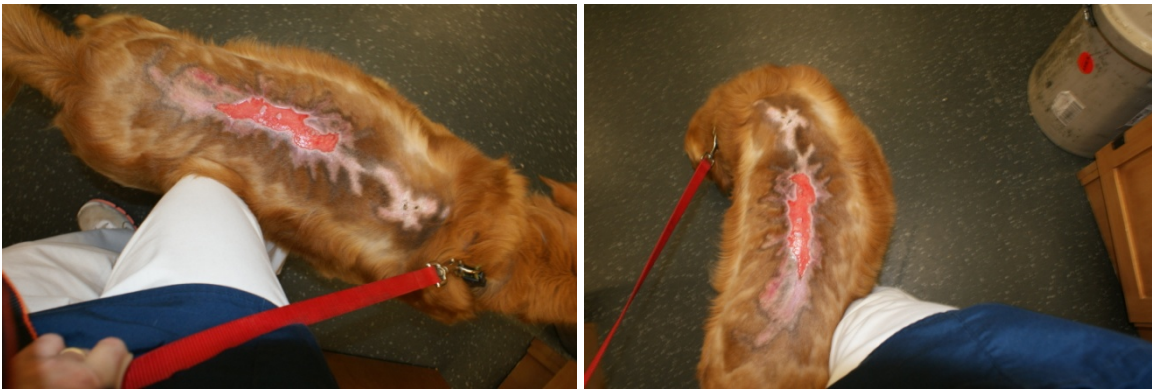




25 Days Post Surgery



37 Days Post Surgery Last 3LT® Treatment



120 Days Post Surgery-Note complete hair regrowth in affected areas.

