

# PALLIATIVE CANCER CARE USING FREQUENCY-SPECIFIC LOW LEVEL LASER THERAPY: FOUR CASE REPORTS

---

*Jeff Grognet, DVM, BSc(Agr) and Louise Janes, BSc(Agr), DVM*  
Mid-Isle Veterinary Hospital, 5 – 161 Fern Road West, Qualicum Beach, British Columbia,  
Canada, V9K 2K1, 250-752-8969, [jgrognet@shaw.ca](mailto:jgrognet@shaw.ca)

## **Conflict of Interest Statement**

Drs. Jeff Grognet and Louise Janes are private practice veterinarians, with no paid connection to the Erchonia Corporation that manufactures the laser device employed in this case report.

## **Abbreviations**

FSLLL: Frequency-specific low level laser

CCF: Chaos conversion factor

## **Abstract**

Four cases of cytologically diagnosed, histologically diagnosed, or presumed malignant neoplasia managed with frequency-specific low level laser therapy in dogs are described. In each of these cases, the therapy resulted in temporary tumor regression and improvement in clinical signs associated with the cancer. Specific laser frequencies along with chaos conversion factor frequencies for third (and fourth) bodies were utilized to manage four cancer patients with a class two laser. Further research is needed to optimize the selection of frequencies for managing specific cancers in individual companion animals.

## **Introduction**

Frequency-specific low level laser therapy (FSLLLT) is currently being used to manage a myriad of disease conditions in companion animals. The potential of FSLLLT can be fully realized with the use of the Erchonia base station laser.

The class two laser (a) has been described in a prior publication (1). The laser utilized was designed to re-establish communication systems of the body using the elements that emulate the energy type (photonic light), the wavelength (635 and 405 nm), the energy level

(5 milliwatts), as well as the frequencies that are inherent to all biological systems.

The use of this laser depends on the delivery of specific frequencies of light (in the correct form) to elicit healing. In work done by Dr. William Inman (2), FSLLLT enhances the body's ability to solve its own problems by putting the cells of the body back into communication with one another. This has been applied to a wide variety of disease processes, with a recent focus on determining the frequencies needed to trigger healing in conditions such as neoplasia, endocrine disease, and immune disease.

Based on previous work (2), it has been suggested that in these complex disorders, there are third and sometimes fourth body influences that hold the problems in place. These bodies are commonly (though not exclusively) the colon, liver, lung, or skin. Delivery of the inherent

frequencies of these tissues (20 Hz, 53 Hz, 21 Hz, and 363 Hz, respectively) alone is not enough to re-establish cellular communication.

Inman created the chaos conversion theory where specific frequencies can speak to aberrant third (and fourth) body tissues that are held out of communication with the body. These frequencies can be calculated. For example, the third body chaos conversion factor (CCF) for the colon is 43.82 Hz. This is calculated by raising the number 20 (the inherent frequency) to the power of  $\log_4$  over  $\log_3$  (which is 1.2618).

Directing the necessary CCF frequency to the body appears to be the key to re-establishing the communication needed to promote healing in complex conditions such as neoplasia.

---

## case 1

### Retroperitoneal Mass: Soft Tissue Sarcoma

A 9-year-old, castrated male Labradoodle was presented for a general examination following an unusual episode of aggression towards another dog. He exhibited sensitivity with palpation of the epaxial muscles of the lumbar spine, but more importantly, a mass was detected in his caudal dorsal abdomen. The mass could not be palpated rectally on this initial exam.

On ultrasound examination (b), a 13 cm by 4 cm by 7 cm infiltrative mass was found in the caudal retroperitoneal space. The mass was closely associated with the aorta, vena cava, and the internal and external iliac arteries. Based on the location, size, and infiltrative nature of the mass, a retroperitoneal sarcoma (nerve root tumor, spindle cell sarcoma, fibrosarcoma) was strongly suspected. No measureable evidence of metastasis was seen in the abdomen, but thoracic radiographs were not performed.

Surgical removal was considered an unfavorable option due to the involvement of the blood vessels. The owner decided to use FSLLLT for palliative care of the tumor and to manage the dog's back pain, rather than pursue

chemotherapy for the tumor alone. Based on this decision, getting a definitive diagnosis with a needle aspiration was declined. The laser frequencies were chosen in attempts to address both the tumor as well as the musculoskeletal pain (see **Table 1** on page 30).

An intensive therapy schedule was instituted. The patient was lasered twice daily for 3 days, daily for 4 days, then twice weekly. After 18 days and 12 sessions, the patient was quite active and moving well, indicating that his pain was greatly diminished. On abdominal palpation, the mass was felt to have grown, but from the benefit seen with the musculoskeletal pain, the owner decided to continue treatment. The frequencies for orthopedic pain were removed but those for the sarcoma were continued.

By day 45, the patient was running 6 kilometers with the owner and had a great appetite. On day 68 the dog deteriorated (19<sup>th</sup> treatment). Once again, he had heat and discomfort in his lumbar area. Frequencies to relieve the inflammation in the spine were added to his frequency set. When the dog presented again 3 weeks later, his

signs were much improved. Frequencies for pain were periodically used throughout the course of treatment to keep his spine comfortable.

The laser therapy was continued on roughly a monthly basis. The 25<sup>th</sup> treatment was done on day 166. The mass felt the same size as it did when it was first detected. On day 178, the mass size was noted to be stable. The patient was not treated again until day 298. At that time, the mass was not palpably enlarged, but the surface was more irregular in texture.

Over the next 12-week period, the patient received additional FSLLLT (with appropriate light frequencies) that addressed other medical conditions – an anal sac abscess and two bouts of ileocolitis.

As well, a new CCF frequency (for liver tissue) was added. Until that time, the frequencies provided by Inman for sarcomas had been employed – those for bladder and skin. On day 325, the mass was significantly smaller on abdominal palpation and it was smaller yet again when it was felt on day 352 (31<sup>st</sup> treatment).

The patient was reassessed on day 449 because he started having difficulty defecating. The mass was much larger, irregular, and had invaded the entire pelvic canal,

restricting stool passage. He received his 36<sup>th</sup> treatment that day.

A stool softener was introduced (Peg 3350, 1 teaspoon PO q 12 h or to effect) (c) to allow easier passage of the feces. The laser sessions were increased to 3 times that week and twice weekly for a further 3 weeks. After one session, the patient was more comfortable but still straining. By day 459, he was not straining; he was passing stools of varying sizes (still on the stool softener).

On day 466, the mass in the abdominal cavity had decreased noticeably by abdominal palpation. It was even smaller on day 491. When assessed on day 544, the mass was stable in size.

On day 552, the patient was presented because he was unable to urinate. The abdominal component of the mass had once again grown significantly. A catheter could be passed, but the dog could not urinate unassisted. He was lasered that day and he subsequently managed to urinate on his own for 2 days. Reobstruction occurred on day 555, at which time euthanasia was elected by the owner.

**TABLE 1: LASER FREQUENCIES USED TO MANAGE THE SARCOMA AND OTHER CONDITIONS IN CASE 1**

	<b>"a" head</b>	<b>"b" head</b>	<b>"405" head</b>
Musculoskeletal Inflammatory Pockets & Pain Sarcoma	4-33-60-151 9-16-42-53 4-777-60-151	465-20.5-25-666 465-20.5-25-666 53-240-20.5-1884	45.2-8166-1550-36 155.6-155.7-279-111 1698.6-55.15-10000-5000
Diarrhea Colitis	4-33-60-151 20-96-784-440	784-16-66-96 880-216-465-25	83-2949-776-727 43.82-46.6-10000-5000
Anal Sac Infection Sarcoma (Liver CCF)	784-1260-69-72 4-33-60-151	21-73-216-363 10000-5000-230-777	1884-36-47-46 149.86-1884-53-55

## case 2

### Large cell/Lymphoblastic Lymphosarcoma

A 15-year-old neutered, male German shorthaired pointer was presented for acute onset of facial edema, including the upper and lower jaws, muzzle, and eyelids. On examination, severe mandibular and prescapular lymphadenopathy was found and fine needle aspirates were performed on the lymph nodes.

While waiting for a definitive diagnosis, the edema was managed with FSLLLT. Frequencies for lymphatic drainage were utilized (see **Table 2**). The patient was on the anti-inflammatory meloxicam (d) (0.1 mg/kg PO q 24 h) for chronic arthritis treatment. The owner was asked to stop the meloxicam that day in case prednisone therapy was needed in the future.

Cytologic findings became available the next day (day 2) with a diagnosis of lymphosarcoma (LSA), large cell/lymphoblastic type (e). The owner was given the option of chemotherapy, but this was declined due to cost and the age of the patient. Because the edema had resolved overnight

and with the apparent success of the treatment, the owner elected to pursue a course of FSLLLT for the LSA as well as his arthritic pain (see **Table 2**).

Therapy began on day 3 and was repeated on days 8, 11, 14, 16, 23, 24, 29 and 38. The treatment regime was dictated by the owner's personal work schedule. By day 8, the patient was feeling good, moving well and his lymph nodes were estimated to have decreased to about half their original size. By day 14, all lymph nodes were of normal dimensions. The dog was feeling well with excellent mobility. He had initiated play in the snow, which the owner had not seen for a long time.

On day 44, there was an acute recurrence of the peripheral lymphadenopathy. Prednisone (f) (1 mg/kg PO q 24 h) was prescribed as a rescue therapy combined with the antacid/proton pump inhibitor omeprazole (g) (1 mg/kg PO q 24 h). The patient failed to respond, his appetite fell, and he was euthanized 5 days later.

**TABLE 2: LASER FREQUENCIES USED TO MANAGE THE LYMPHOSARCOMA AND EDEMA IN CASE 2**

	"a" head	"b" head	"405" head
Lymphatic Drainage	45-24-54-47	15-250-230-146	279-111-100-55
Lymphosarcoma	20.5-666-2187-1260	83-73-53-465	317.12-145.65-96-25
Inflammation	4-33-60-151	20-66-73-43 363-21-59-97	9-16-42-53 155.6-155.7-36-2
Lymphosarcoma	10-234-78-46	363-21-59-97	155.6-155.7-36-2

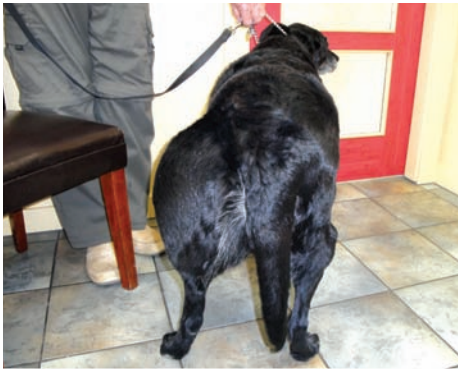

Figure 1. Case Report 3 at the start of FSLLT

The patient, an 11-year-old neutered, female Labrador retriever, was presented to the hospital with a massively swollen left hind leg. The leg had become markedly enlarged over the previous 24 hours. Radiographs revealed mild arthritis in the stifle but no evidence of a bone tumor. An infection and a soft-tissue tumor were considered the most likely differential diagnoses. The dog was started on marbofloxacin (h) (1.45 mg/kg PO q 24 h) and an aspirate was taken of the enlarged leg.

Pathology was suggestive of a myxosarcoma due to a homogeneous population of spindle cells (e). These tumors are considered to be locally aggressive and challenging to remove due to their infiltrative nature. Because the tumor surrounded the coxofemoral joint, complete excision was considered unlikely. Limb amputation was declined.

Due to the edema distal to the mass, the dog was started on prednisone (f) at a tapering dose beginning at 20 mg PO BID (0.44 mg/kg PO q 12 h). The edema resolved, but the bulk of the mass remained unchanged. The prednisone was tapered and treatment concluded over a 14-day period.

Eight months later, the patient was reassessed for a new left hindlimb lameness. The tumor had grown and seemed to be interfering with the mechanical movement of the leg. Because pain was also a likely contributing factor to her abnormal ambulation, meloxicam (d) (0.1 mg/kg PO q 24 h) was dispensed. On a follow-up phone call, the owner reported that the dog was moving somewhat better. The meloxicam dose was tapered to about half the full dose and maintained at that level until the next reassessment.

Four months later, the patient was presented due to inappetence. A physical examination revealed a fever (39.7°C), massive enlargement of the leg (Figure 1), but no edema or lymphadenopathy. The patient was put on marbofloxacin (h) (1.45 mg/kg PO q 24 h) due to the fever.

Though the owner thought there was an initial improvement in appetite, it was apparent 9 days later that the patient was not feeling any better and was barely eating. A course of FSLLT was initiated, including frequencies for pain, the malignancy, as well as appetite stimulation (day 1) (see Table 3).

Over the following 5 days (and 7 treatments), the patient showed continuous improvement and she was eating normally. Four days later, her appetite fell again and she seemed uncomfortable at night. For this reason, meloxicam (d) (0.1 mg/kg PO q 24 h) was reintroduced. This improved her mobility and she was more interactive. The anti-inflammatory was continued daily.

On day 18, the leg distal to the tumor began to swell with edema. Frequencies for lymphatic drainage were added (see Table 3). Three days later, on recheck, the fluid had mostly resolved.

By day 40, the patient was running with the owner, aggressively taking sticks from the other dogs, and swimming in the pond. Treatments were continued every 2 to 3 weeks with the last treatment on day 146. The leg remained stable in size with no edema. The patient remained active, was eating well, and feeling good overall through this time. On the day of euthanasia (day 157), the patient developed bloody diarrhea, was depressed, and refused food.

**TABLE 3: LASER FREQUENCIES USED TO MANAGE THE MYXOSARCOMA AND OTHER CONDITIONS IN CASE 3**

	"a" head	"b" head	"405" head
Pain - general	9-16-25-465	125-3-100-2720	46.6-333.89-666-727
Loss of appetite	151-60-9-4	42-59-33-16	279-111-20.5-216
Cancer (general)	4-33-60-151	10000-5000-3176-2720	2489-2189-2084-2050
Musculoskeletal	9-16-42-53	465-25-666-20.5	45.2-8166-1550-36
Lymphatic drainage	15-42-250-230	20.5-100-279-111	45.2-1699-279-111

## case 4

### Large, Non-cleaved Cell Lymphosarcoma

A 14-year-old castrated male Border collie presented with a peripheral lymphadenopathy. A fine needle aspirate cytology (e) was consistent with large cell lymphoma. As well, his walk was stilted and painful, and he resisted palpation of his rigid spine. He was started on Tramadol (i) (2.3 mg/kg PO q 8–12 h) for pain control.

Chemotherapy was discussed but declined due to the patient's age. The owner elected to pursue FSLLLT to manage the malignancy and the dog's pain (see **Table 4**).

The treatment schedule followed an intensive program, twice a day for 3 days, then once daily for 4 days, followed by twice weekly for 4 weeks. The frequency of treatment was subsequently adjusted according to the patient's needs.

After the first day of treatment, the patient was reported to be more alert and he had slept more comfortably. After 2 days, the lymph nodes were palpably softer and were about one-half the original size. By day 4, the patient was feeling well enough to initiate play. The tramadol was reduced to one-half the starting dose. This medication was continued on an "as needed" basis throughout the treatment period.

On day 15, the patient became very active which caused an intense aggravation of his back pain. To assist in pain management, the patient received a spinal adjustment (Veterinary Neuronal Adjustment (VNA)) (j) and was given meloxicam (d) (0.1 mg/kg PO q 24 h) which helped ameliorate the discomfort and re-establish his appetite.

On day 29, the day of the patient's 16th treatment, palpation revealed that his lymph nodes were of normal size. His pain was well controlled, but he presented with a head tilt without a nystagmus, as well as mild balance issues on ambulation. Early geriatric vestibular disease was diagnosed. VNA was performed to improve neurological messaging and to provide continued support for his spine. As well, laser frequencies were added to hasten resolution of the vestibular condition (see **Table 4**).

By day 52, the head tilt was resolved and the patient was feeling well. The owner was giving daily or every-other-day meloxicam. The owner was cautioned to limit the dog's exuberant activity to prevent reinjuring the back.

On day 70, the lymph nodes were mildly enlarged. The frequencies were changed to include a CCF fourth body frequency (see **Table 4**). A week later (day 85), the lymph nodes had shrunk to normal size.

On day 122, the lymph nodes increased in size yet again. This episode occurred after a period of extreme activity and subsequent severe back pain. The patient was treated daily with FSLLLT for 5 days, and the lymph nodes again regressed in size.

The patient was euthanized on day 136 following an acute episode of unrelenting pain and refusal to eat.

**TABLE 4: LASER FREQUENCIES USED TO MANAGE THE LYMPHOSARCOMA AND OTHER CONDITIONS IN CASE 4**

	"a" head	"b" head	"405" head
Lymphosarcoma, pain, incontinence (4 sets)	4-33-60-151	10000-5000-777-230	83-73-1550-66
	45-36-46-363	465-20.5-25-666	8166-2167-1260-1151
	55-97-96-100	125-454-153-5	9-16-42-53
	59-21-78-234	43-20-784-24	155.6-155.7-279-111
Lymphosarcoma, new inherent frequency	4-33-60-151	10000-5000-777-230	145.65-73-1550-66
Lymphatic drainage	59-21-71-20.5	146-250-15-363	100-155.7-279-111
Vestibular	4-33-60-151	9-16-42-47	178.95-5.75-61-4

## Discussion:


Laser has many diverse applications in veterinary medicine. Historically, laser use in patients with cancer has been dissuaded because of the belief that it augments cancer cell growth (3). Though this may be true for the more powerful units, very weak units, such as the Erchonia laser, are being used for successful palliation of cancer in companion animals.

The patients in these case reports were managed with FSLLLT because the owners did not want to pursue surgical intervention or chemotherapy. FSLLLT is an excellent option in managing cancer because it can promote “quality of life” with no side effects. Also, frequencies can readily be added/adjusted to address the ever shifting imbalances of the whole patient, not just those associated with the patient’s cancer. This is especially important in geriatric patients that typically suffer from a myriad of disorders concurrently.

In the cancer patient cases presented in this article, FSLLLT extended the patients’ lifespan, with good quality of life,

beyond what would have been expected had FSLLLT not been implemented for the presenting clinical problems. The tumor-associated clinical signs were very well-managed and some temporary tumor control was also provided. This was particularly evident in the two dogs with lymphoma.

The laser frequencies chosen for each patient were based on recommendations from Inman (2). The addition of CCF frequencies for third (and sometimes fourth) bodies to the treatment regime of cancer patients appears to play an important role in the response to FSLLLT. This is a novel approach that needs continued investigation.

These case reports document the positive effect of FSLLLT on canine cancer patients needing palliative care. Further investigation is needed to determine additional light frequencies that will prove beneficial to individual companion animals with specific forms of cancer. 

---

## ENDNOTES:

- a. The Erchonia laser consists of three class 2 laser heads (“a” head is red, 635 nm; “b” head is red, 635 nm; and “405” head is violet, 405 nm) inserted into a charging and programming station. Each head is programmed to deliver four frequencies of light, for a total of 12 frequencies, in three-minute sessions.
- b. SonoVU Ultrasound Incorporated, interpreted by Radiology Vet Consulting, Toronto, Ontario, Canada
- c. Peg 3350, Medisia, St. Laurent, Quebec, Canada
- d. Metacam, Boehringer Ingelheim, Burlington, Ontario, Canada
- e. True North Veterinary Diagnostics, Burnaby, British Columbia, Canada
- f. Apo-Prednisone, Apotex Inc, Toronto, Canada
- g. Losec, Atrazeneca, Mississauga, Ontario, Canada
- h. Zeniquin, Pfizer, Quebec, Canada
- i. Ultram, Janssen Inc, Toronto, Ontario, Canada
- j. Veterinary Neuronal Adjustment, VOM Seminars Inc, Coeur d’Alene, Idaho, USA

## REFERENCES:

1. Jeff Grognet, Louise Janes. Resolution of a Large Non-healing Wound in a Dog with Frequency-Specific Low Level Laser Therapy. *J Am Hol Vet Med Assoc* 2013;34:24-29.
2. Dr. William Inman, VOM Seminars Incorporated, personal communication
3. Lucio Frigo, Juliana SS Luppi, Giovanni M Favero, et al. The effect of low-level laser irradiation (Ga-Al-AsP - 660nm) on in vitro and in vivo melanoma. *BMC Cancer* 2009;9:404.