

Erchonia Laser Case Study – Wound Healing Throatlatch Surgery

Dick Vetter, DVM - Buckley, WA

- Wes
- Brittany
- 4 Years Old

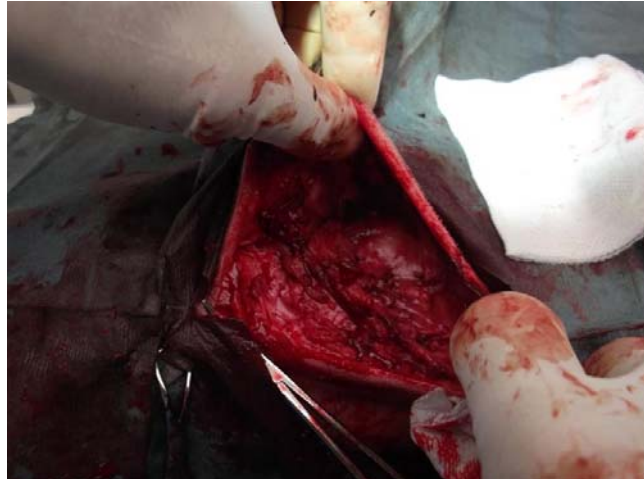
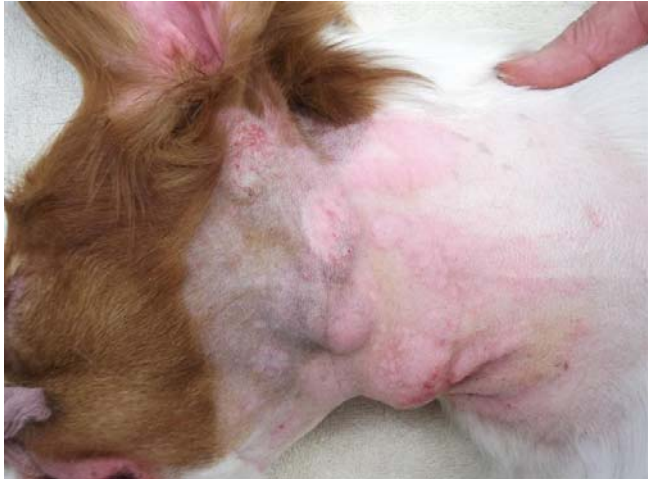Wes is a 4 year old Brittany field trial show dog. 5 ½ weeks ago, I did a major surgery on several chronic abscesses in the throatlatch region. Obviously, I had to do a pretty significant shave job of the area and the surgery had the added potential of a big scar.

The owner was HOPING that we wouldn't have to shave much hair, as she wanted to get back in the show ring as soon as possible. She also understood the necessary protocol for aseptic surgery.

Last week, she brought Wes in, 5 ½ weeks post op and ecstatically showed us the results of our surgery and the laser therapy (which she THOROUGHLY believes in now). The scarring is minimal.

I have attached pre-op, surgery and the images taken last week.

Another interesting note that she pointed out was that we had shaved his left hind lower leg to place a Fentanyl (pain) patch. We did not laser that area and the hair had not grown back in like the surgical area that we focused on with the laser therapy.



August 8, 2012

Foothills Veterinary Hospital
28512 - 112th St. E.
Buckley, WA 98321

Dear Dr. Vetter & Staff,

We wanted to give you an update on Wes - the field trial/show Brittany. As you remember, he had extensive intricate surgery on his neck on July 2, 2012. My daughter & I were chagrined that his neck hair had to be closely shaved off, although we knew it was absolutely necessary for his surgery. We knew he would be out of the show ring for a minimum of 6 to 9 months waiting for the hair to grow back.

In addition to his medications following his surgery, you also prescribed cold laser therapy treatments. We had never heard of this treatment and you gave us a "crash course". Wes had a total of 18 laser therapy treatments over a period of 2-3 weeks following his surgery. We want you to know that we are firm believers of this innovative therapy treatment because of Wesley! The incision on his neck (show side) was not pretty in the beginning and my daughter & I both thought his show days were probably over. Not so, thanks to the cold laser therapy treatments the incision healed beautifully, there appears to be no residual scar tissue inside and his hair on his neck has grown back remarkably fast. Believe it or not, he is entered in the Olympic Kennel Club shows coming up on August 18 & 19, 2012 at the Enumclaw Fairgrounds... just 1 ½ short months following his surgery!!! All we can say is WOW!

I should have taken pictures of his neck following his surgery to show "before and after", hard to believe without seeing the progress with our own eyes.

Thank you so much for not only performing the intricate surgery, but prescribing the cold laser therapy treatments. THANK YOU!

Sincerely,

Marilynne & Clem Little

Shady's Wild West Kid (Wes), the patient
Marilynne & Clem Little, breeders/owners
Windy Schmidt, daughter & show handler