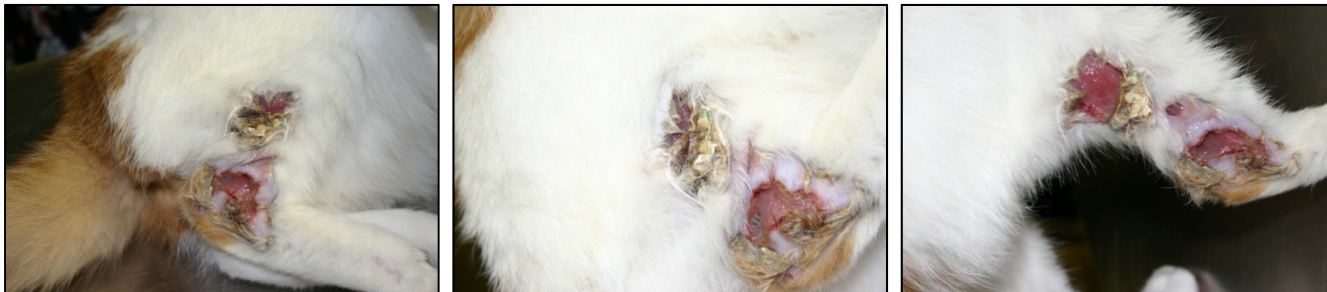


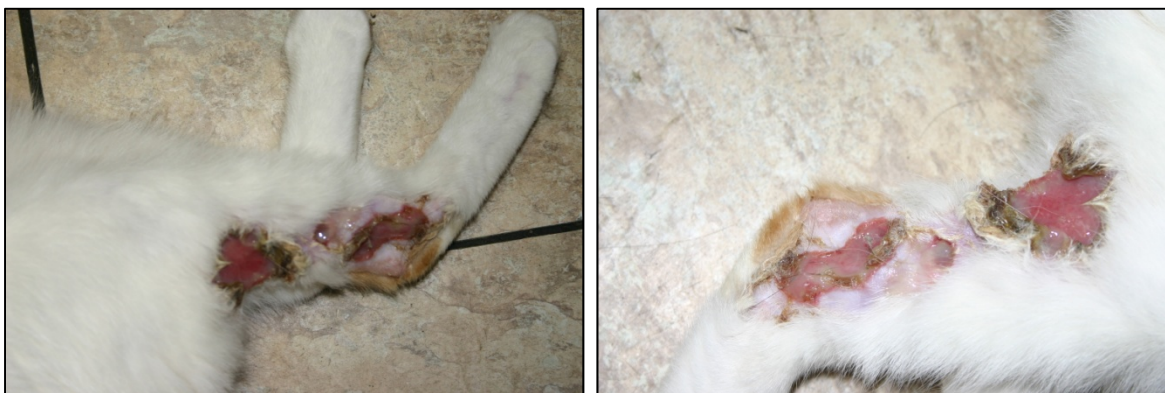**Erchonia Laser Case Study – Biopsy Diagnosis Edematous granulation tissue with severe neutrophilic and granulomatous cellulitis**

Sharon A Johnson, DVM  
Burlington, NJ

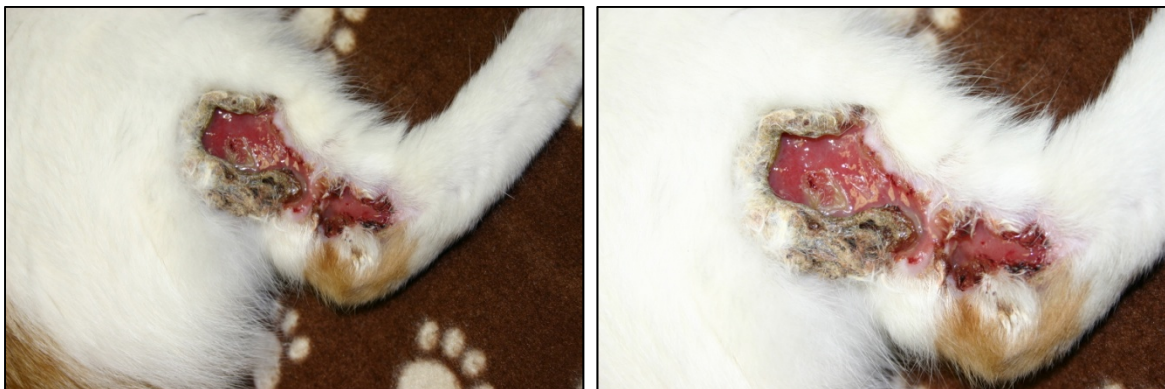3/26/12



3/28/12



4/18/12



Most Recent

