

THE EFFECT OF LOW LEVEL LASER THERAPY ON THE HEALING OF EQUINE BILATERAL DISTAL HINDLIMB WOUNDS

Chase Whitfield
Hank Jann, DVM, MS, DACVS
Ken Bartels, DVM, MS

INTRODUCTION

Low Level Laser Therapy (LLLT) has received attention in recent years as a treatment modality for distal limb wounds in horses. The most accepted mechanism of action of LLLT is increased adenosine triphosphate (ATP) production within mitochondria.¹ The effect of LLLT has been evaluated in depth over the years in laboratory animals, in vitro cell studies, and human patients.^{2,3,4} However, its effect on equine wounds is an area that needs exploration. In comparison to upper body wounds distal limb wounds develop exuberant granulation tissue and also exhibit prolonged healing times

due to decreased epithelialization and wound contraction.⁵ The ability to increase cellular activity and facilitate wound healing is a potential capability of LLLT.

PHYSIOLOGIC MECHANISMS

The physiologic processes enhanced by LLLT include leukocyte infiltration, macrophage activity, collagen deposition, cellular proliferation (myofibroblasts, endothelial cells and keratinocytes), neovascularization, and granulation tissue formation.^{1,4,6,7} The physiologic mechanism of LLLT is its ability to increase cellular respiration via photobiostimulation.¹ This is initiated at

the cellular level by the absorption of light energy by mitochondrial photoreceptors. The enzyme within the mitochondria that is stimulated the most by LLLT is cytochrome c oxidase. Cytochrome c oxidase is the terminal enzyme in the mitochondrial electron transport chain. When this enzyme is affected by LLLT, electron transfer across the mitochondrial membrane is increased resulting in increased oxidative metabolism and ATP production that are imperative for cellular function, metabolism and proliferation (Fig. 1). Systemic effects of LLLT have also been observed due to the release of metabolites into general circulation from the area of treatment. Thus, wound healing is ultimately enhanced by increased cellular respiration.

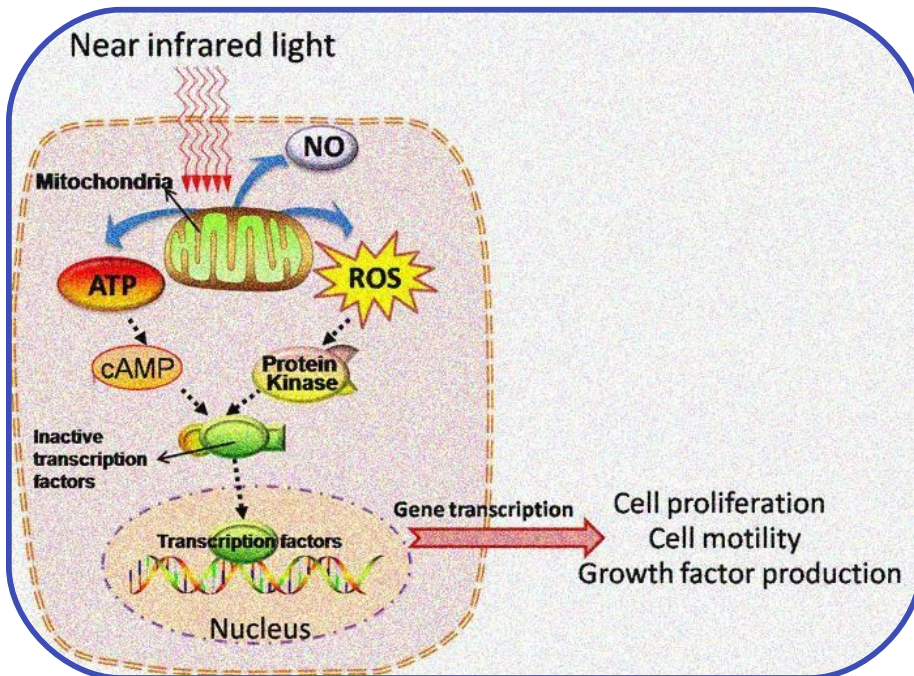


Fig 1. Diagram outlining the physiologic mechanism of LLLT.

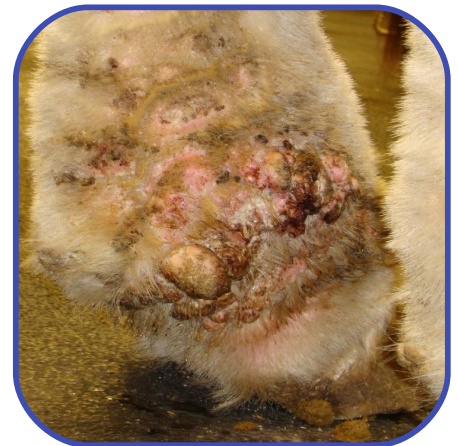

Fig 2. Left hindlimb at presentation.

CASE REPORT

An 11 year old Clydesdale mare presented to Oklahoma State University Veterinary Medical Teaching Hospital on 12/07/2010 with bilateral proliferative, exudative masses on the plantar medial aspect of her hindlimbs from the fetlock

distally to the coronet (Fig.2 and 3). The exact duration and progression of the condition as well as her previous medical history was unclear at the time of presentation because she had recently been rescued by the owners. Aside from the bilateral distal hindlimb masses, no additional significant findings were noted on physical exam.

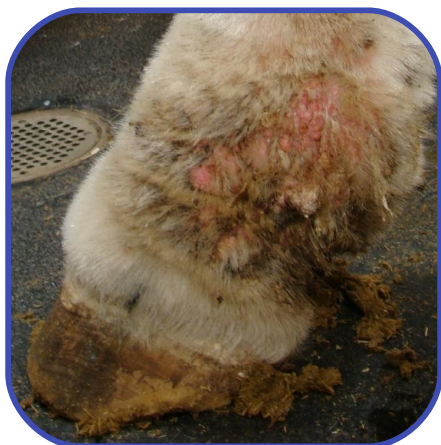

Fig 3. Right hindlimb at presentation.

Surgical debridement was performed on 12/08/2010. The horse was pre-medicated (xylazine/butorphanol/flunixin meglumine) induced (ketamine/diazepam) and maintained under general anesthesia (isoflurane). The hind limbs were clipped and aseptically prepped for surgery. The bilateral distal hindlimb masses were excised with #10 scalpel blade. Electrocautery and postoperative compression bandages were used to control hemorrhage. Histopathologic examination of the masses revealed epidermal hyperplasia with hyperkeratosis and moderate, mature fibrosis (Fig 4 and 5).

Post-operatively the horse received flunixin meglumine (1.1 mg/kg IV BID for 2 days,) procaine penicillin g (22,000 IU/kg IM BID for 5 days) and gentamicin (6.6 mg/kg IV SID for 5 days). Daily bandage changes were performed for 10 days. On 12/13/2010, the horse was treated with trimethoprim sulfamethoxazole (15 mg/kg PO BID for 10 days) to prevent secondary bacterial infection at the surgical sites, LLLT was initiated and daily cleansing was

performed. The LLLT device was a 7.5 milli Watt dual diode, 635 nm, constant wave 3b medical laser^a (Fig. 6). All ANSI laser safety guidelines for use of lasers on health care facilities (Z136.3) were closely observed. LLLT consisted of 5 minutes over the wounds, 3 minutes over the distal limb and 3 minutes over the nerve root (L3) (Fig. 7). Epithelialization and contraction were documented photographically daily (Fig 8 and 9).

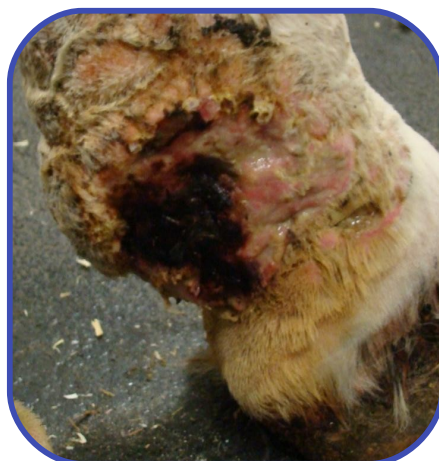

Fig 4. Left hindlimb post-operatively.

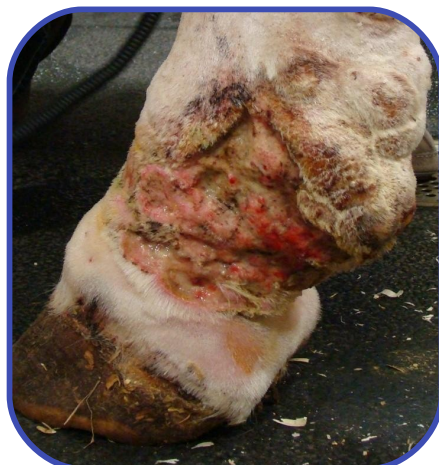

Fig 5. Right hindlimb post-operatively.

DISCUSSION

This report illustrates the clinical application of LLLT in a horse. Our

^a. Erchonia EML, Erchonia Medical Inc.,2021 Commerce Dr., McKinney, TX 75069

clinical impression was favorable because the wounds demonstrated excellent contraction and epithelialization without exuberant granulation. Clinical efficacy has not been documented in the literature.⁸ Although these results are anecdotal, we feel LLLT has great potential in wound management. The physiologic mechanism of LLLT is stimulation of enzymes in the electron transport chain that increase ATP production. The increase in cellular activity at and around the wound enhances wound healing. The use of LLLT for wound treatment in human medicine is well documented; its use in veterinary medicine has not been extensively documented. In the future, LLLT could become a common modality for treatment of equine wounds.



Fig 6. LLLT device used to treat patient.

CONCLUSIONS

This case report documented a favorable clinical impression of LLLT. Further clinical documentation and data obtained from controlled research studies will allow better understanding of physiologic mechanisms and application methodology. In our opinion, LLLT has the potential to be a major form of treatment of equine wounds.

REFERENCES

1. Karu, T. "Low-Power Laser Therapy" Ch. 48 Biomedical Photonics Handbook. Tuan Vo-Dinh Press, 2003.
2. Demidova-Rice, T.N., Salomatina, E.V., Yaroslavsky, A.N., et al. Low-level light stimulates excisional wound healing in mice. *Lasers in Surgery and Medicine* 39: 706-715, 2007.
3. Enwemeka, C.S., Parker, J.C., Dowdy, D.S., et al. The efficacy of low-power lasers in tissue repair and pain control: a meta-analysis study. *Photomedicine and Laser Surgery* 22: 323-329, 2004.
4. Posten, W., Wrone, D.A., Dover, J.S., Arndt, A., Silapunt, S., Alam, M. Low-level laser therapy for wound healing: mechanism and efficacy. *Dermatology Surgery* 31: 334-340, 2005.
5. Jacobs, K.A., Leach, D.H., Fretz P.B., et al. Comparative aspects of the healing of excisional wounds on the leg and body of horses. *Veterinary Surgery* 13: 83-90, 1984.
6. Hawkins, D., Houreld, N., Abrahamse, H. Low level laser therapy (LLLT) as an affective therapeutic modality for delayed wound healing. *Annals New York Academy of Sciences* 1056: 486-493, 2005.
7. Medrado, A.R.A.P., Pugliese, L.S., Reis, S.R.A., Andrade, Z.A. Influence of low level laser therapy on wound healing and its biological action upon myofibroblasts. *Lasers in Surgery and Medicine* 32: 239-244, 2003.
8. Petersen, S.L., Botes, C., Olivier, A., and Guthrie, A.J. The effect of low level laser therapy (LLLT) on wound healing in horses. *Equine Veterinary Journal* 31: 228-231, 1999.



Fig 7. Application of LLLT to the left distal hindlimb wound.

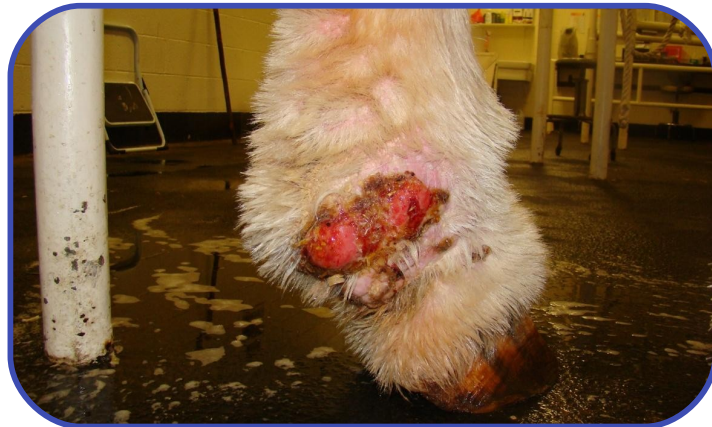

Fig 8. Left hindlimb leg wound on March 9, 2011 (91 days post-op).

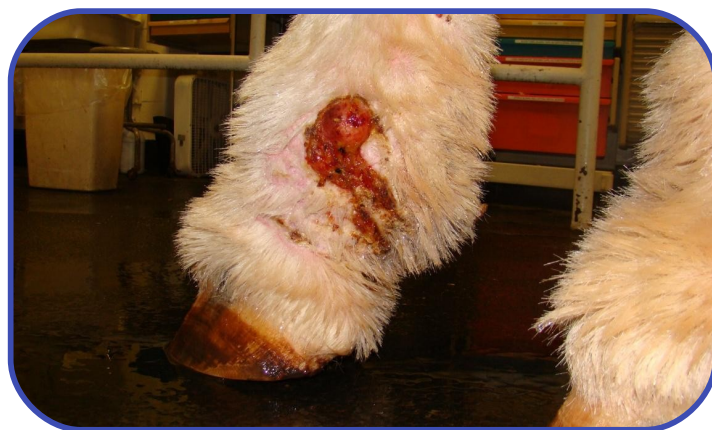

Fig 9. Right hindlimb wound on March 9, 2011 (91 days post-op).